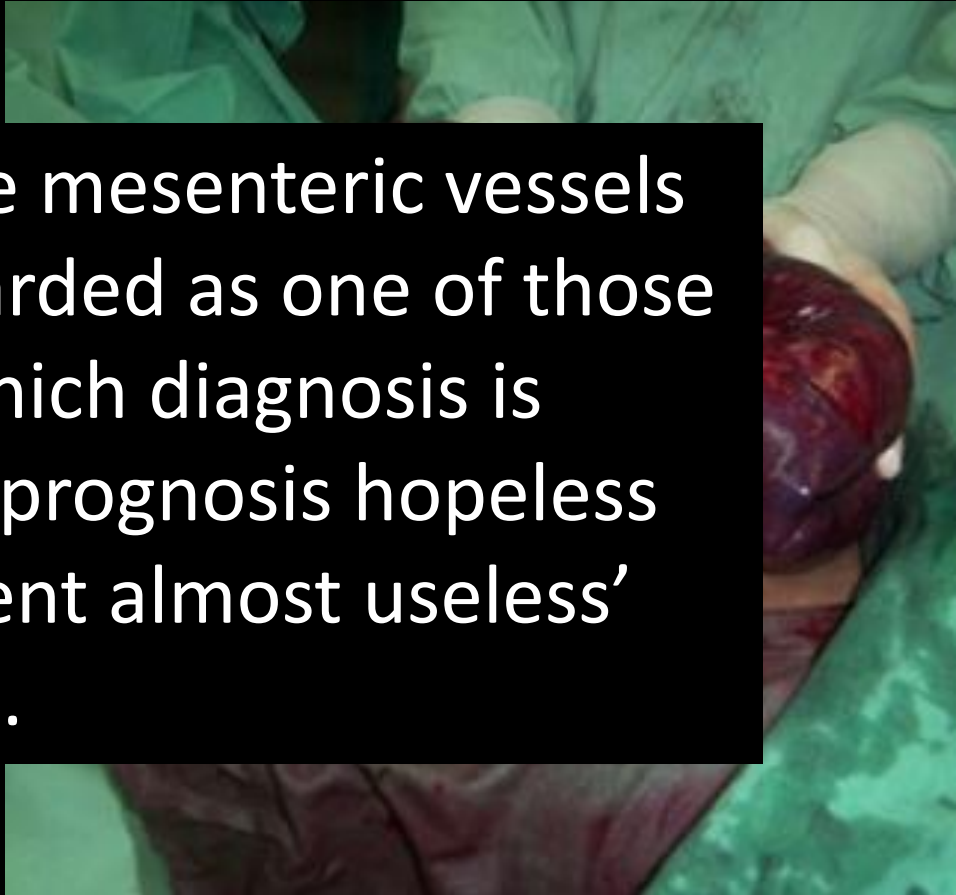
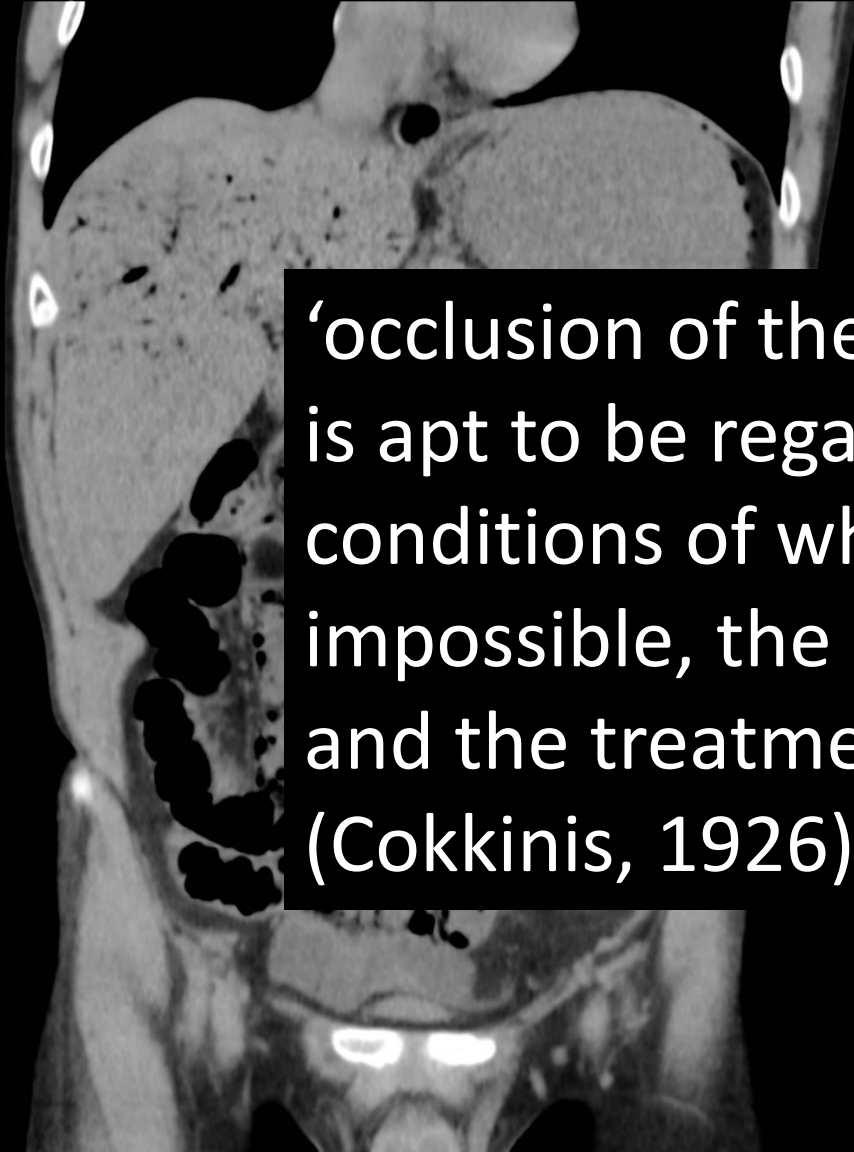


Rigshospitalet

Amazing case

Akut mesenterial iskæmi

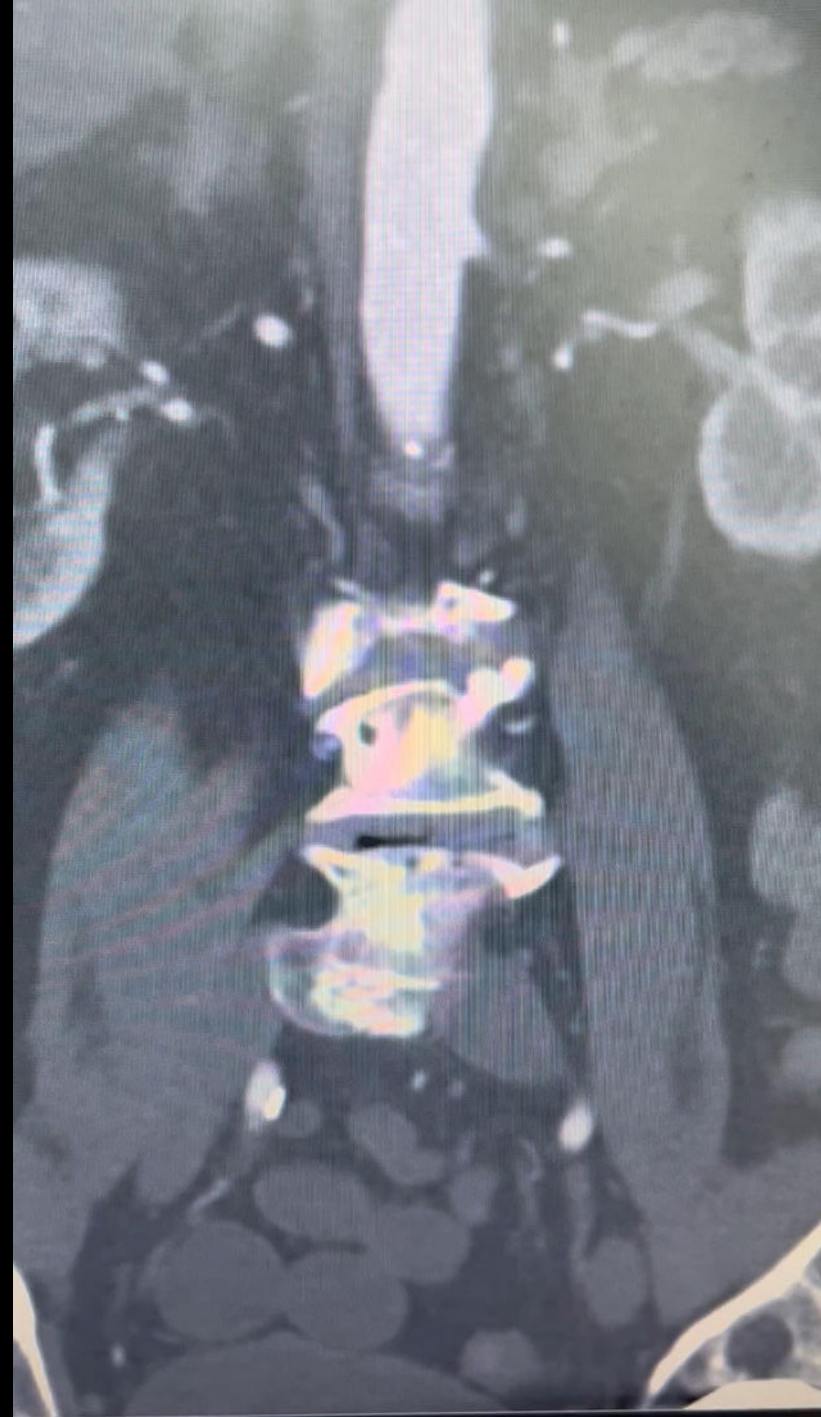




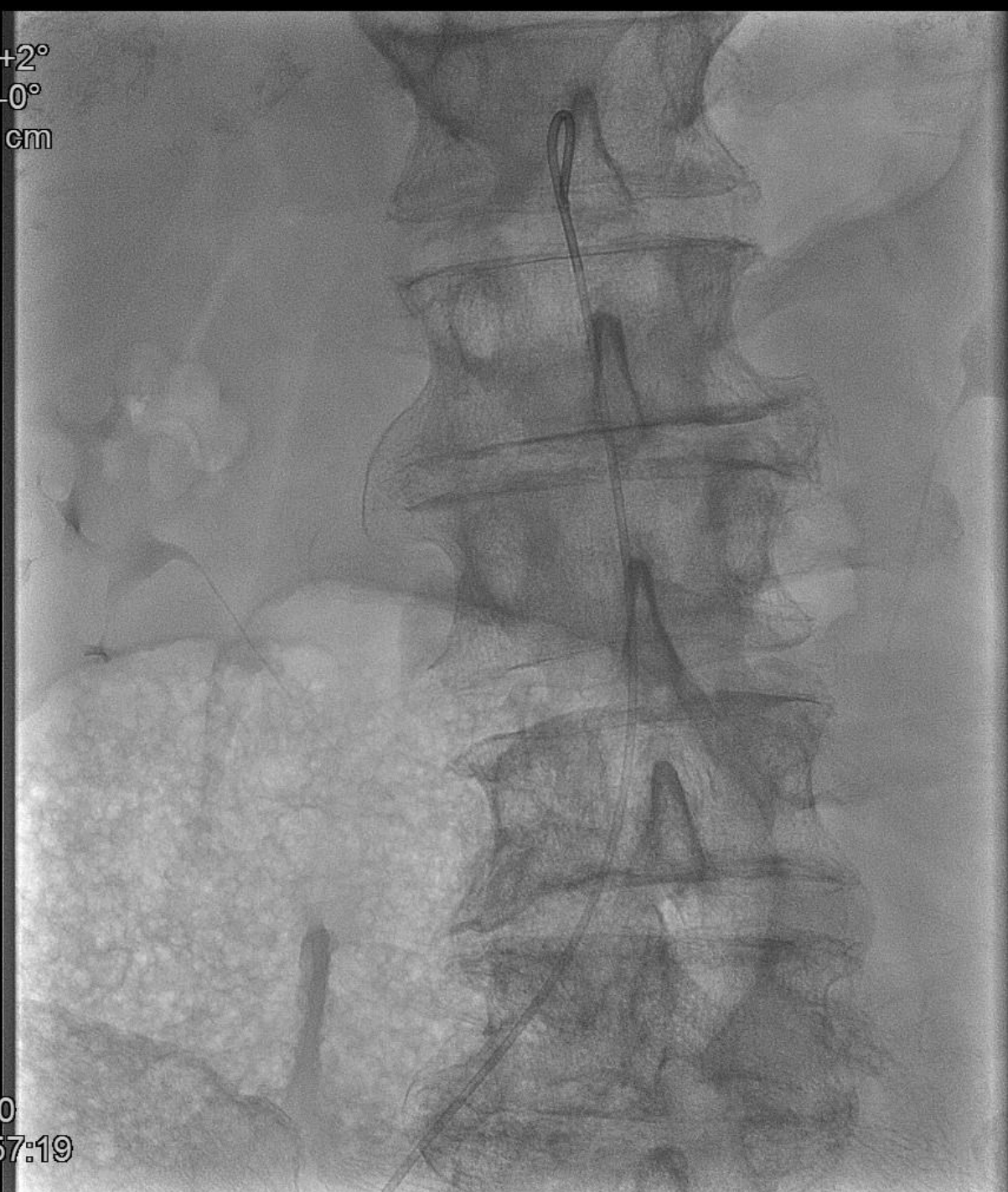‘occlusion of the mesenteric vessels is apt to be regarded as one of those conditions of which diagnosis is impossible, the prognosis hopeless and the treatment almost useless’ (Cokkinis, 1926).

Akut SMA emboli

- 82 årig AFLI patient
- Akut ondt i maven gennem få timer



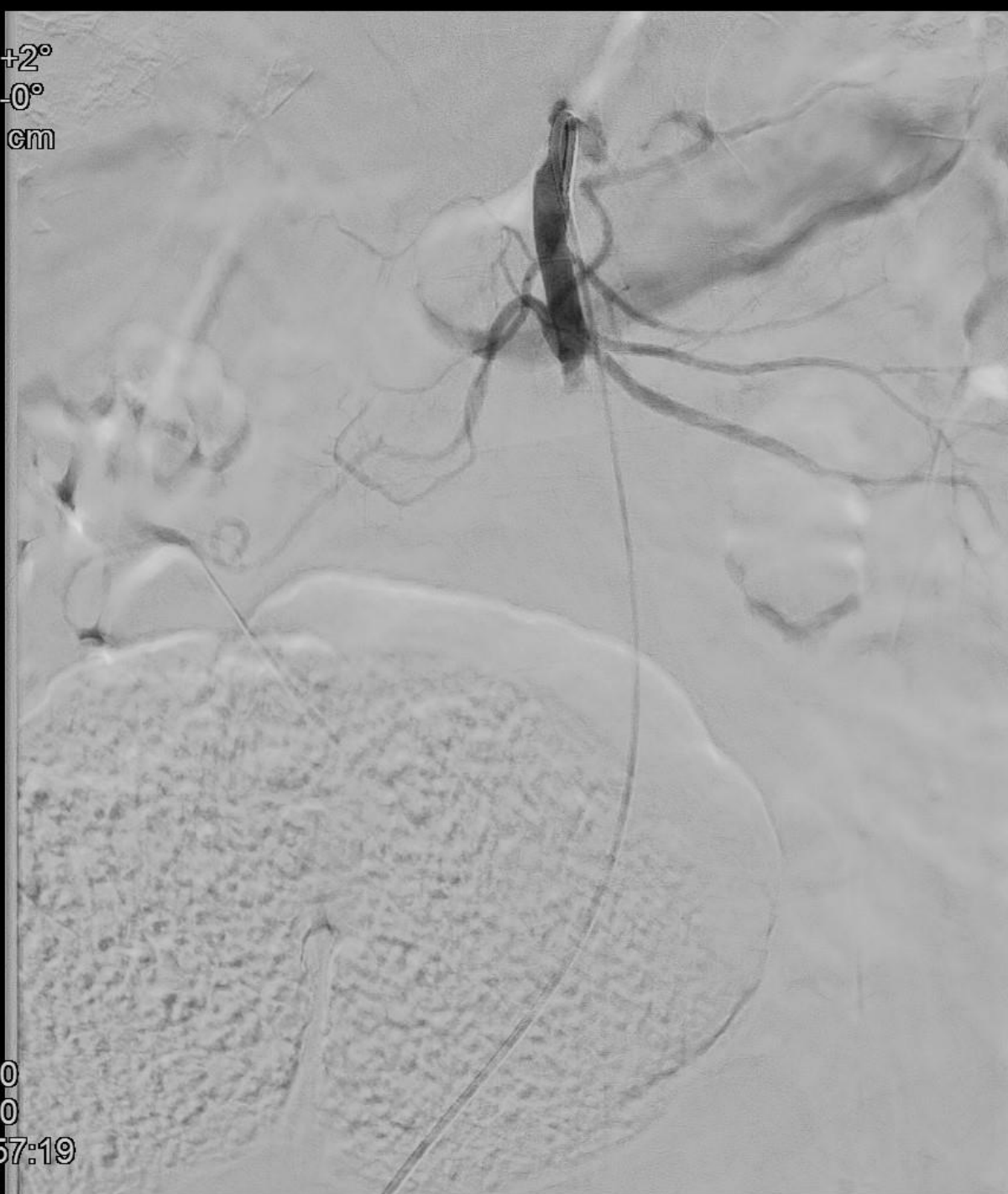Rot +2°
Ang -0°
FD 37 cm



□ 0:50
» 22:57:19

1
2

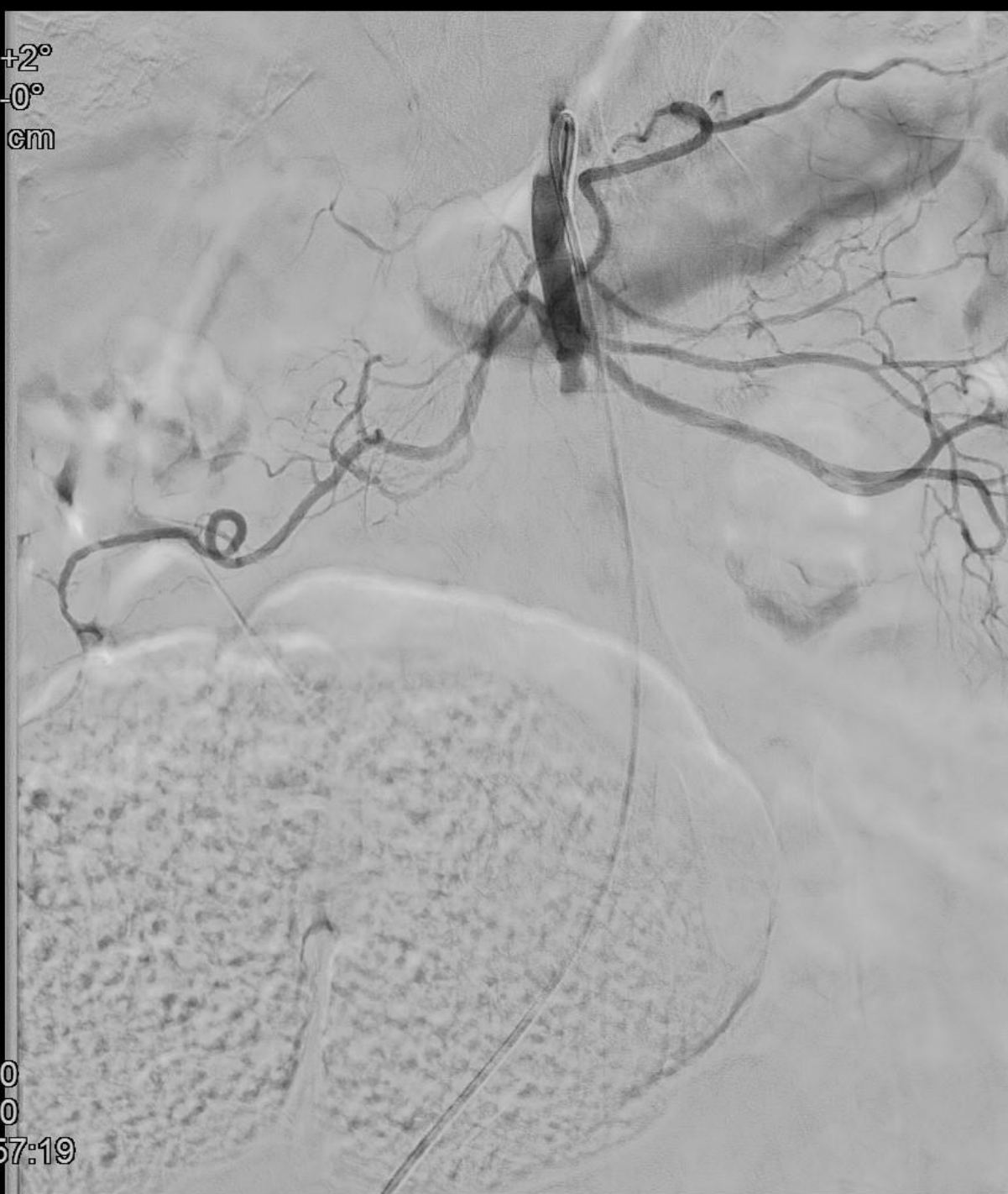Rot +2°
Ang -0°
FD 37 cm



0:00
2:50
22:57:19

1
13-6

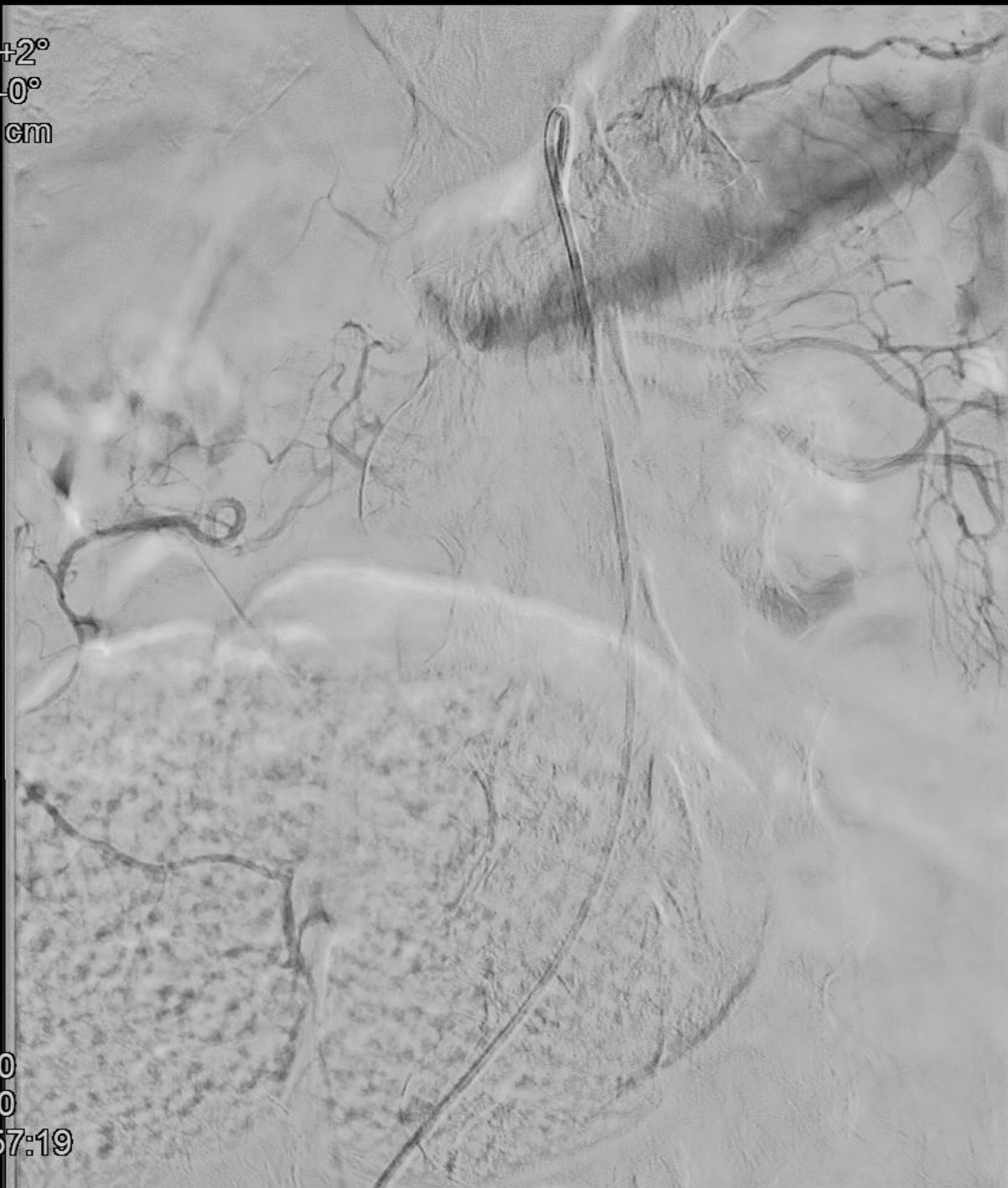Rot +2°
Ang -0°
FD 37 cm



0:00
3:50
22:57:19

1
13-8

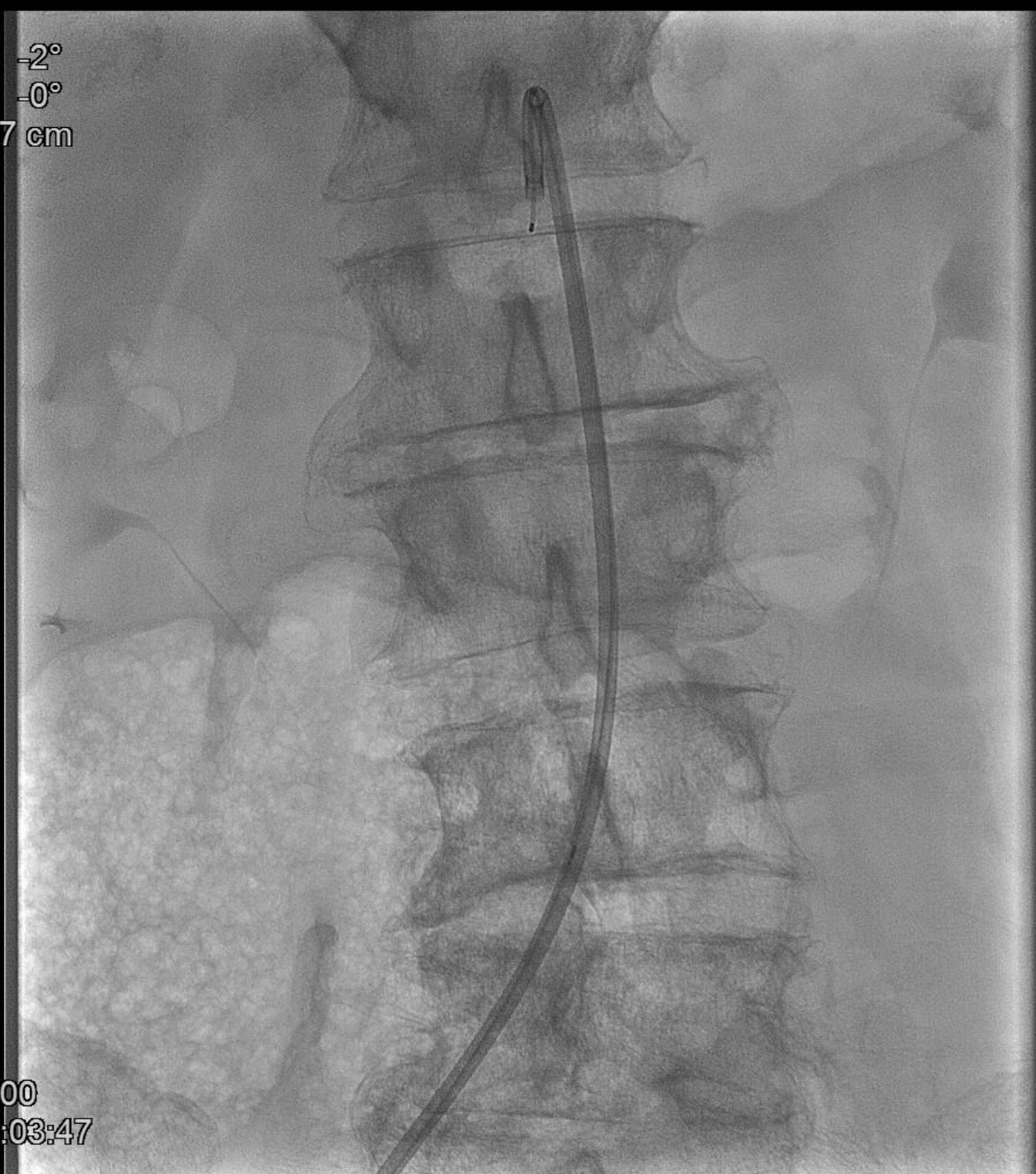
Rot +2°
Ang -0°
FD 37 cm



0:00
4:50
22:57:19

1
13-10

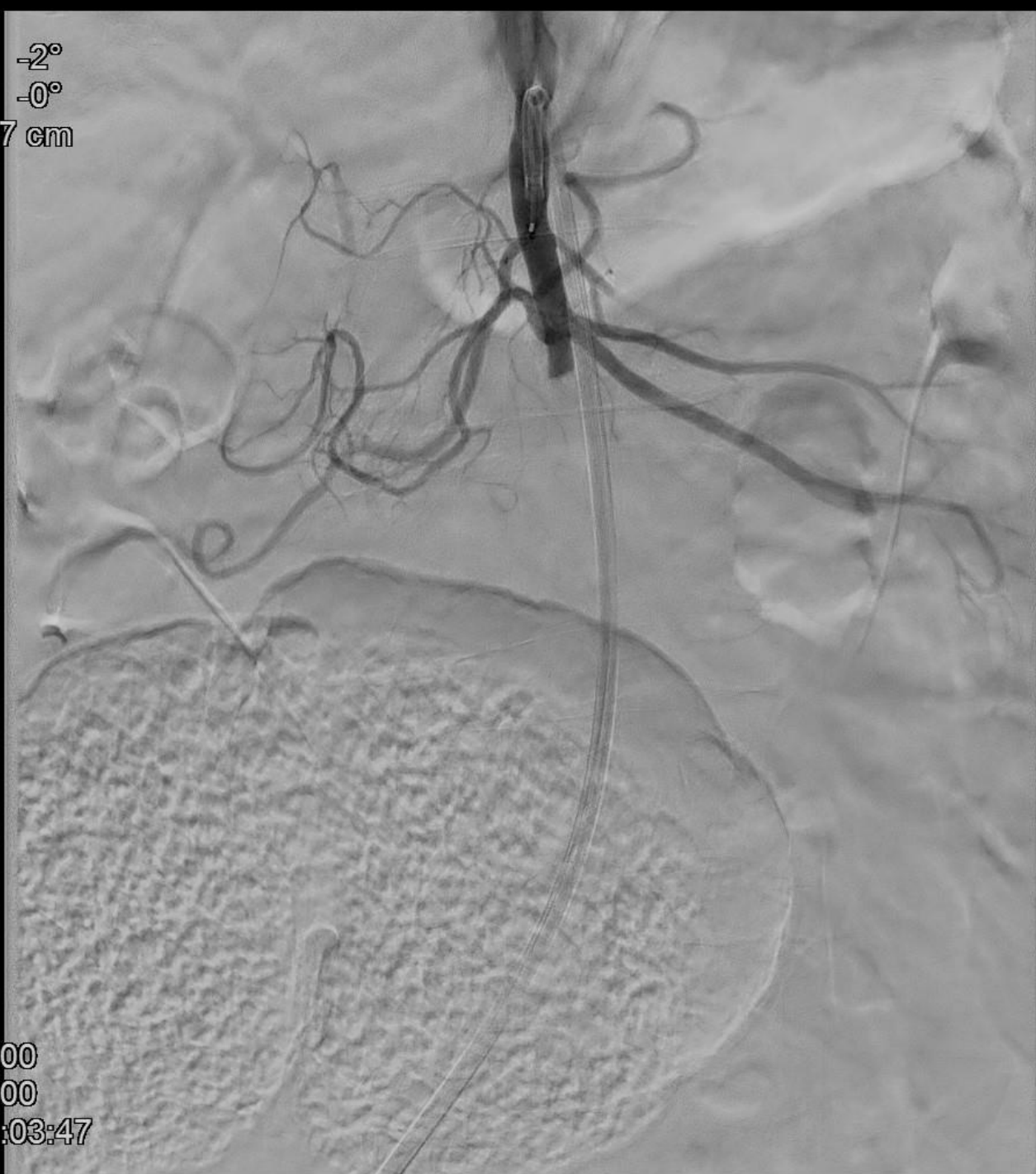Rot -2°
Ang -0°
FD 37 cm



□ 0:00
» 23:03:47

2
1

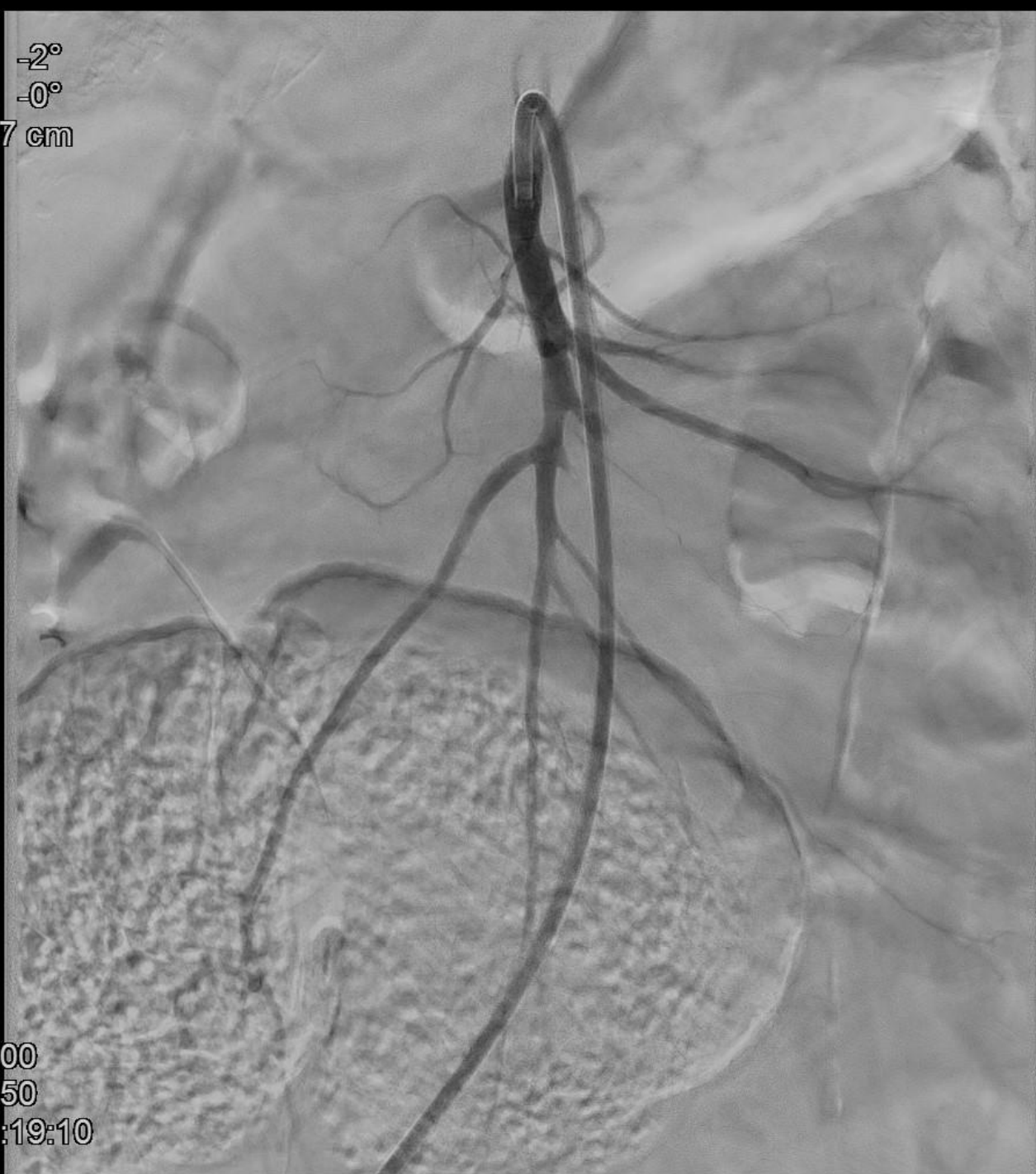Rot -2°
Ang -0°
FD 37 cm



0:00
2:00
23:03:47

2
12-5

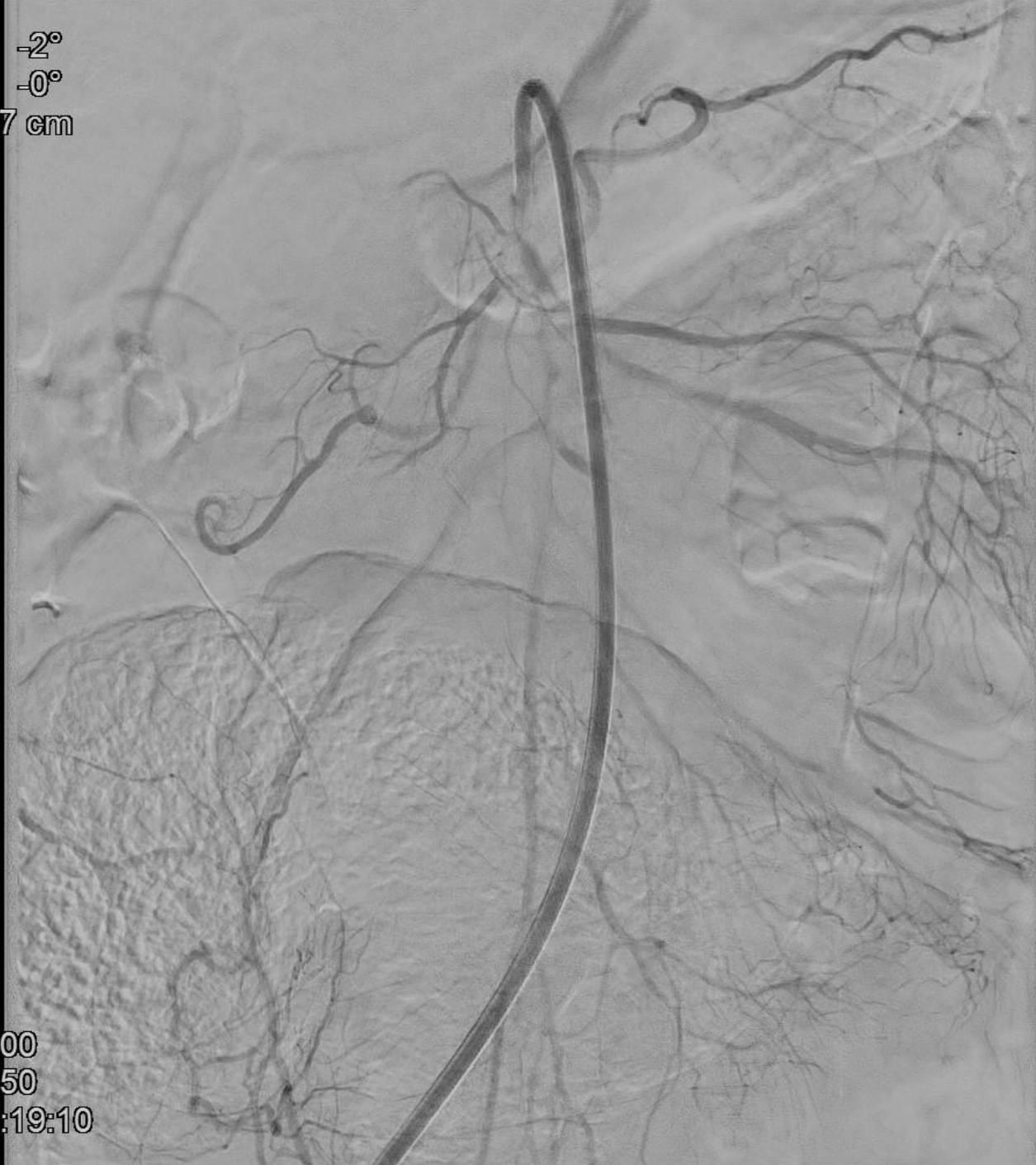Rot -2°
Ang -0°
FD 37 cm



0:00
2:50
23:19:10

3
13-6

Rot -2°
Ang -0°
FD 37 cm



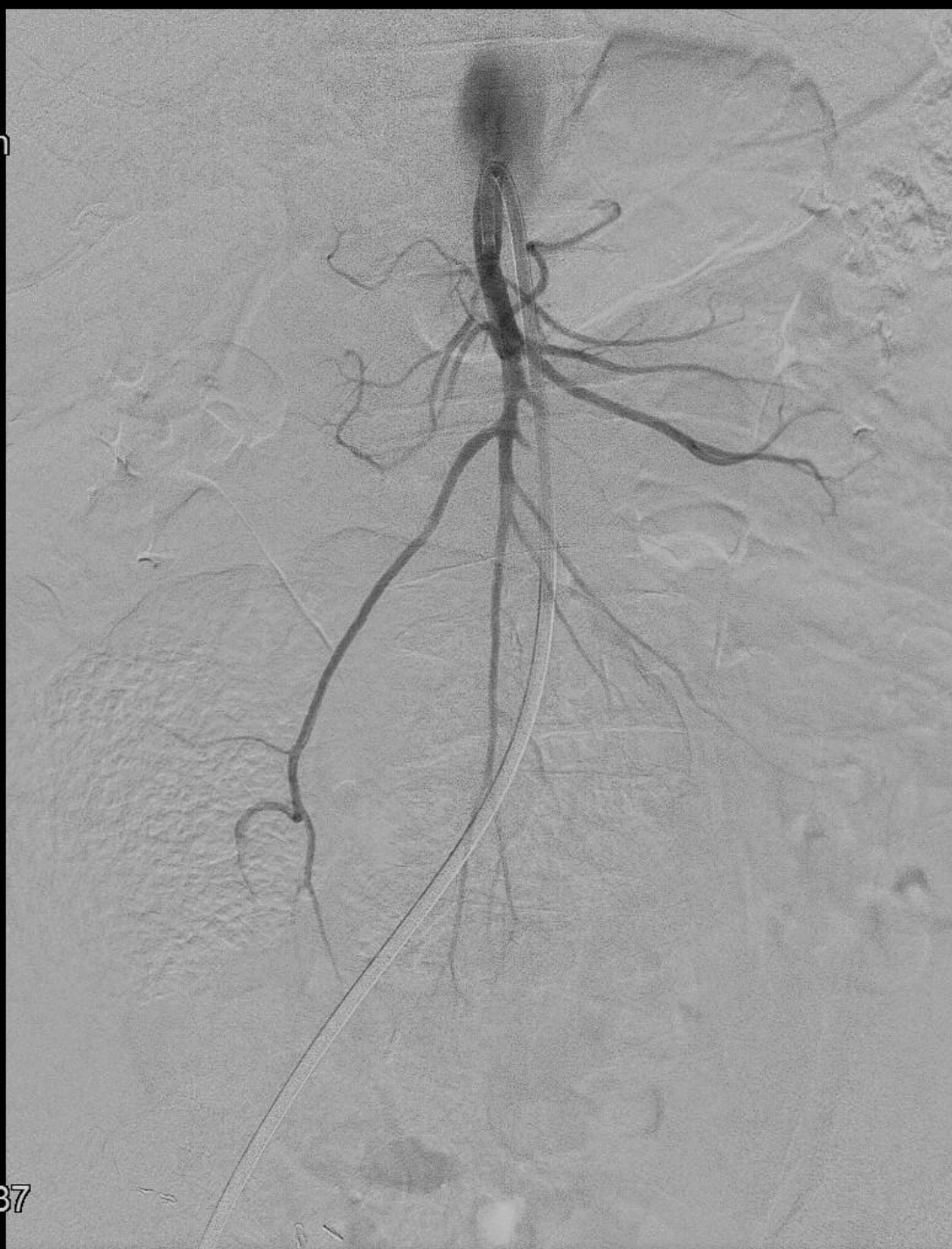0:00
3:50
23:19:10

3
13-8

Rot -2°
Ang -0°
FD 48 cm

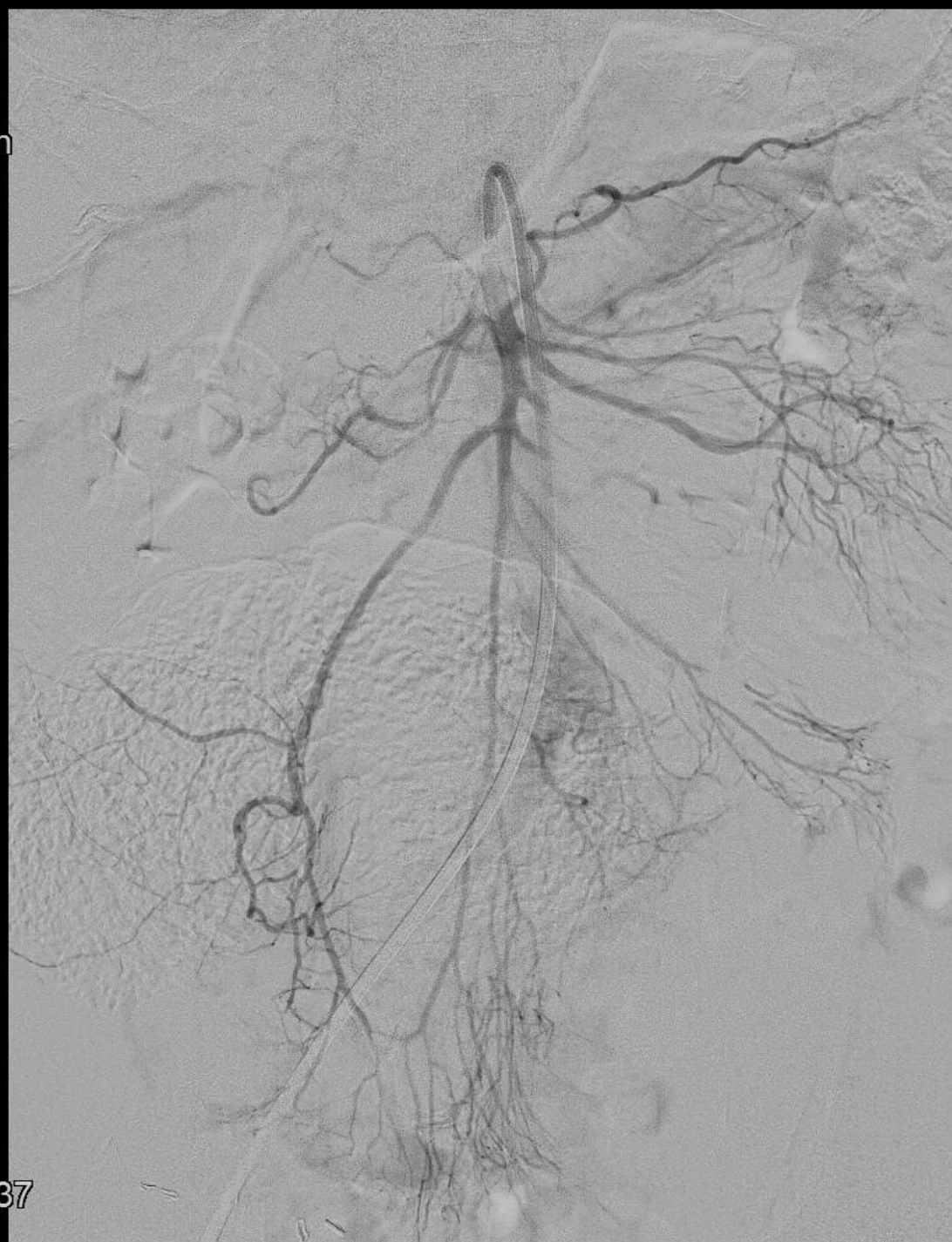

0:50
1:50
23:19:37



4
2-4

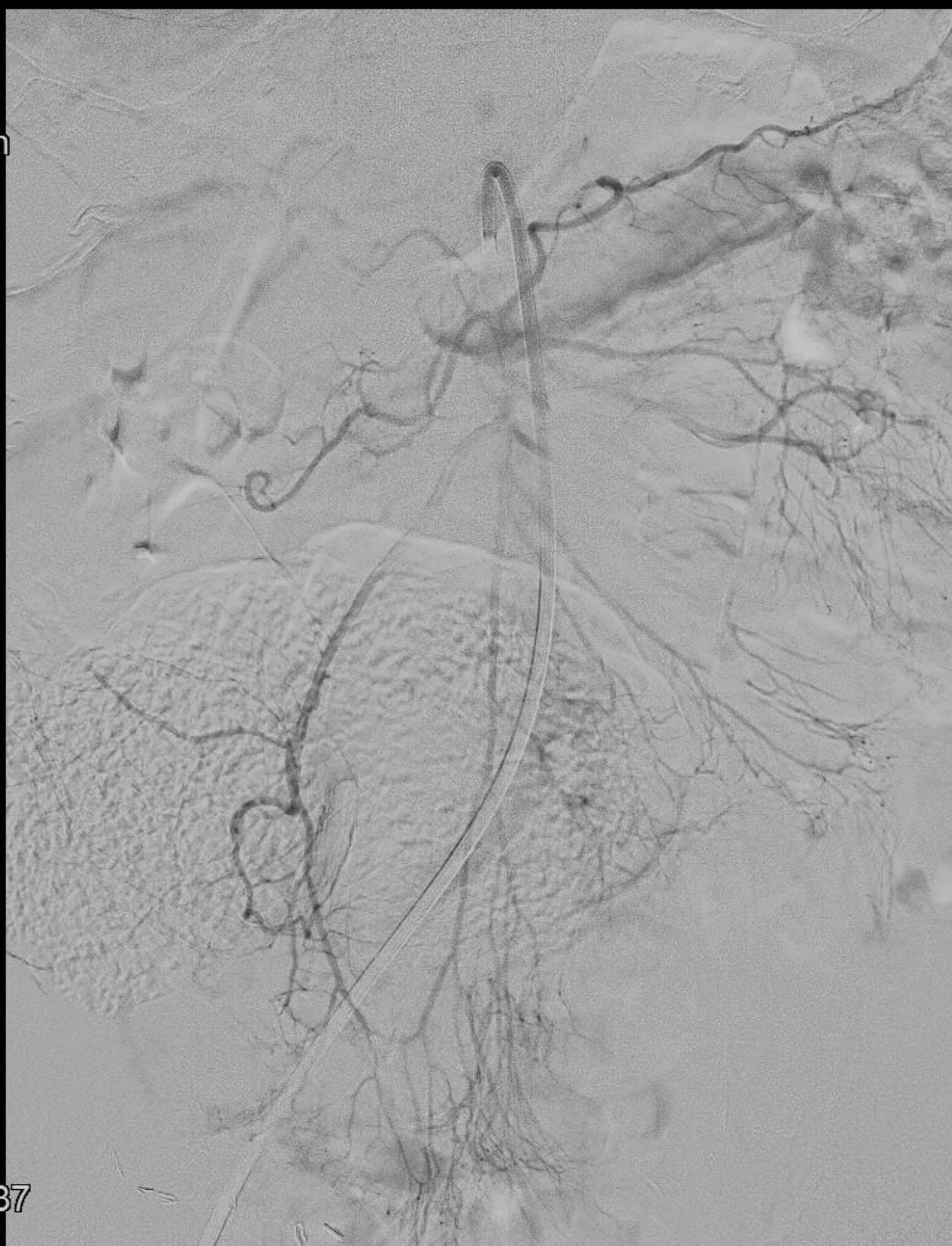Rot -2°
Ang -0°
FD 48 cm



0:50
2:00
23:19:37

4
2-5

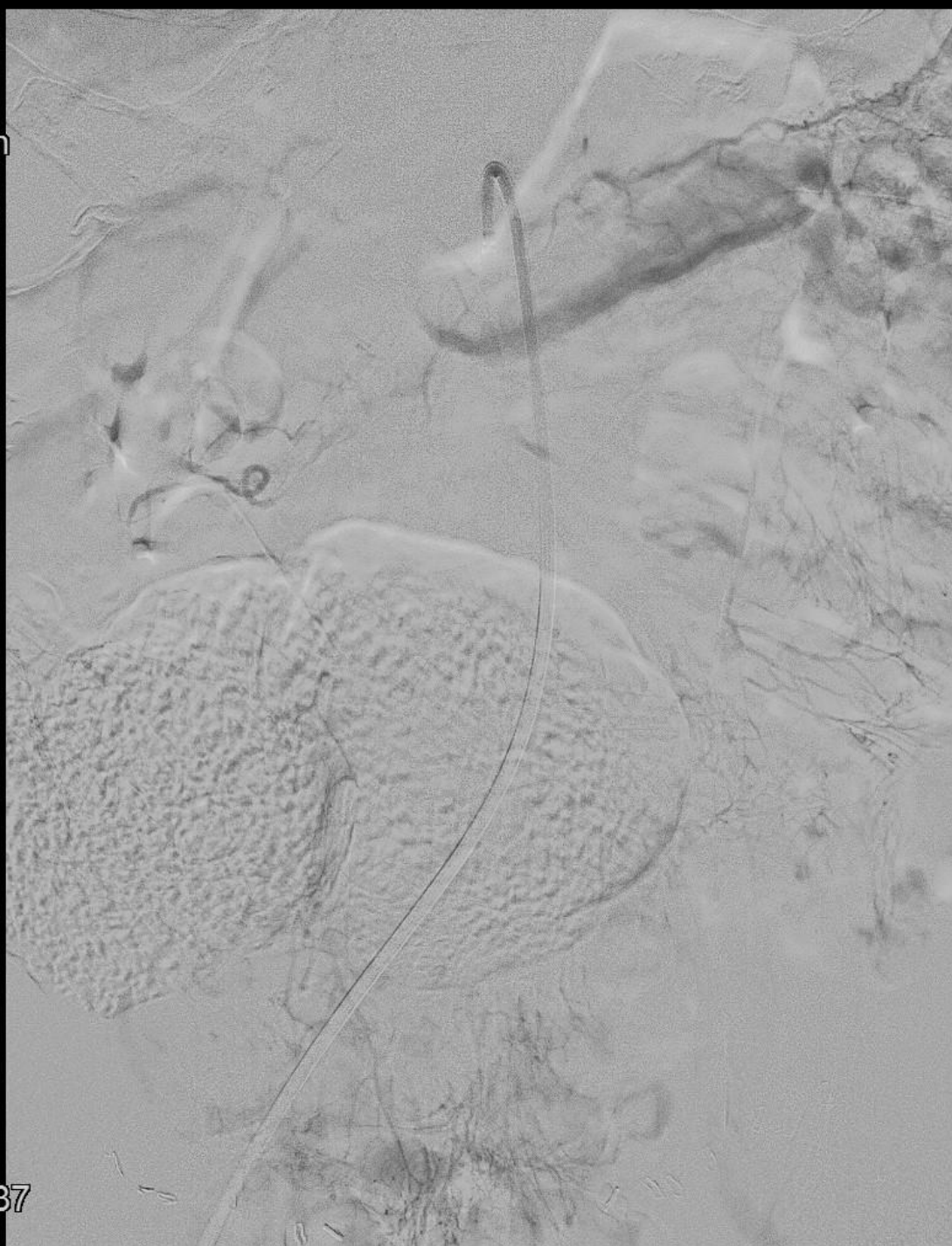Rot -2°
Ang -0°
FD 48 cm



0:50
2:50
23:19:37

4
2-6

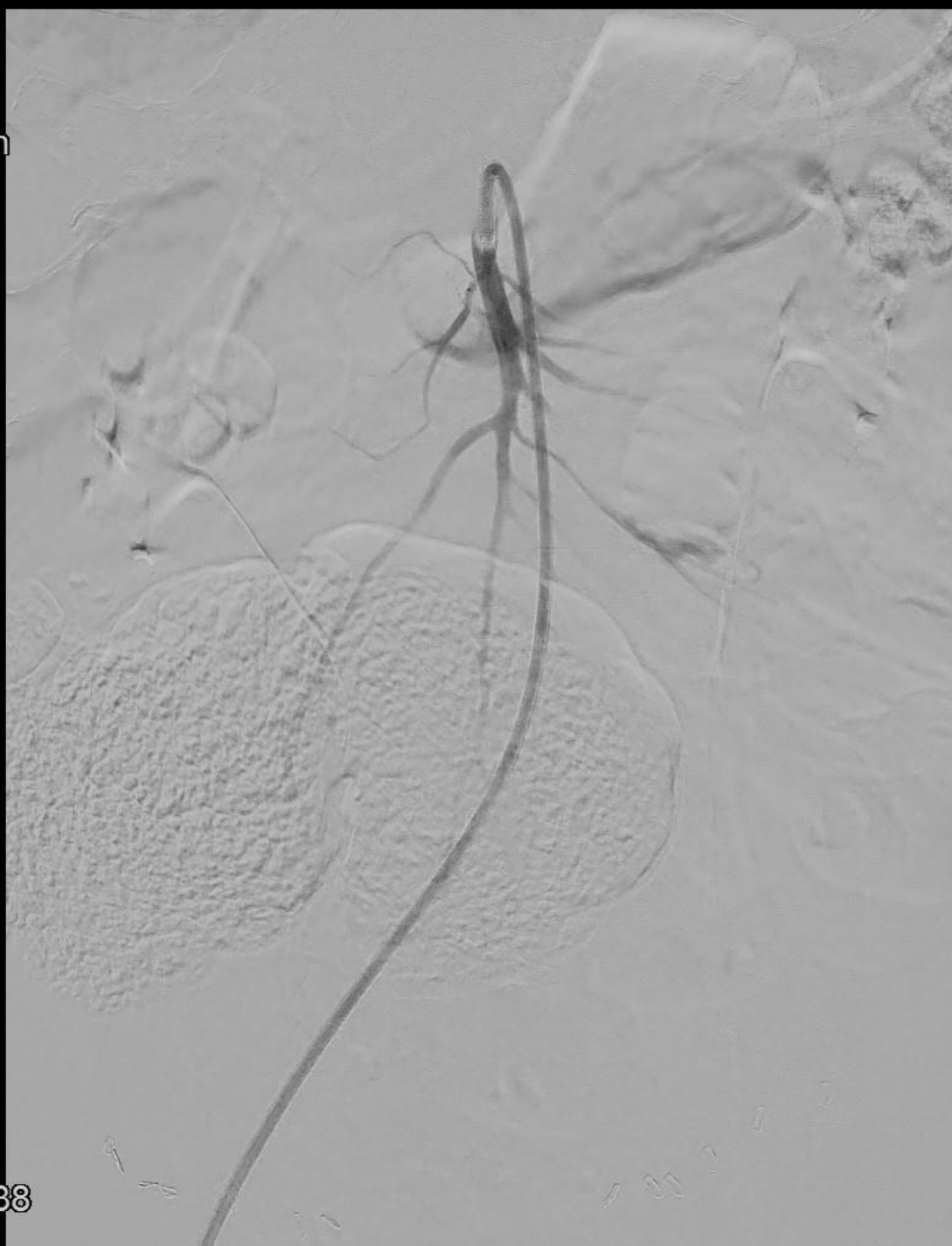Rot -2°
Ang -0°
FD 48 cm



📷 0:50
🕒 3:00
⏮ 23:19:37

4
2-7

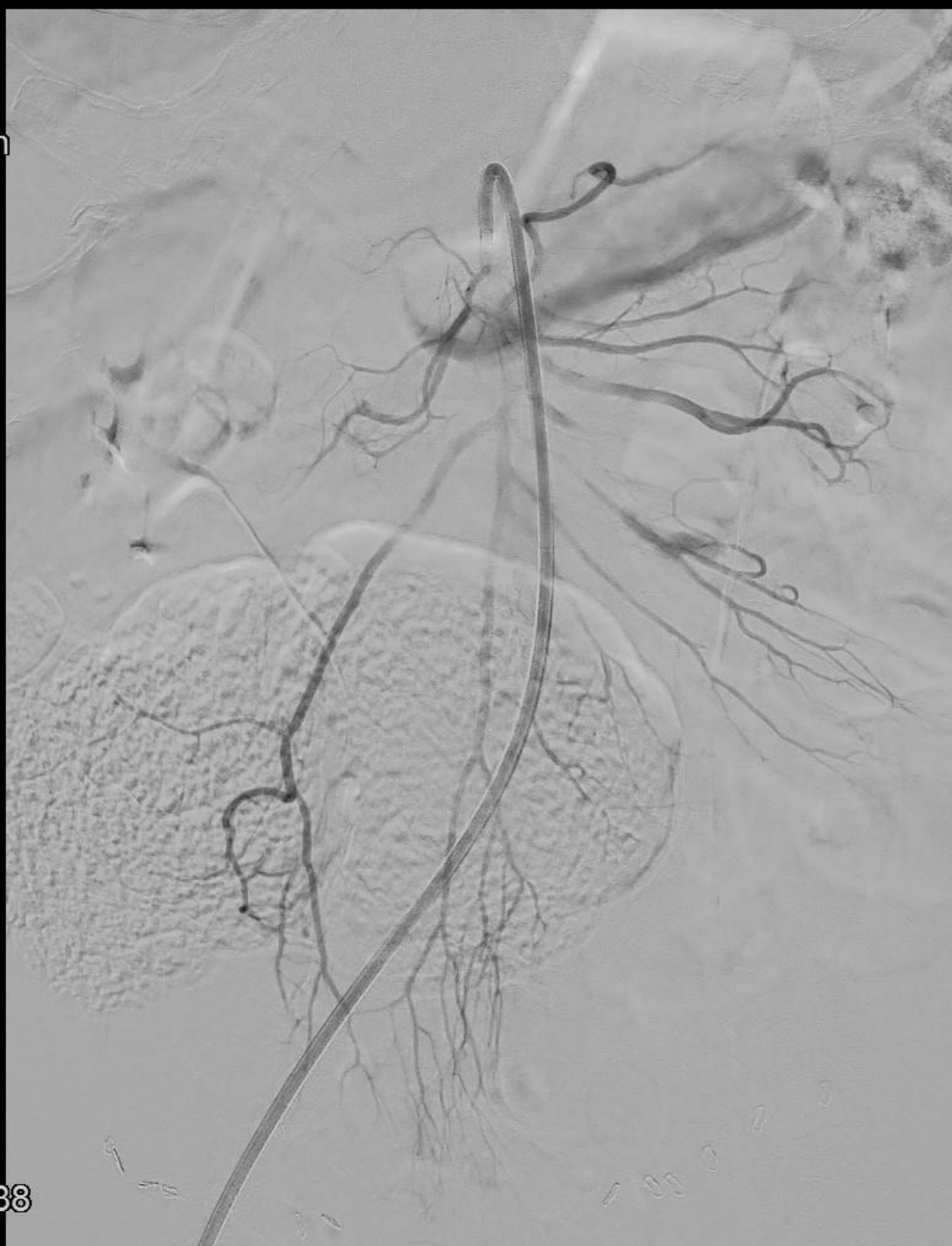Rot -2°
Ang -0°
FD 48 cm



📄 1:50
📄 2:00
▶▶ 23:28:38

6
4-5

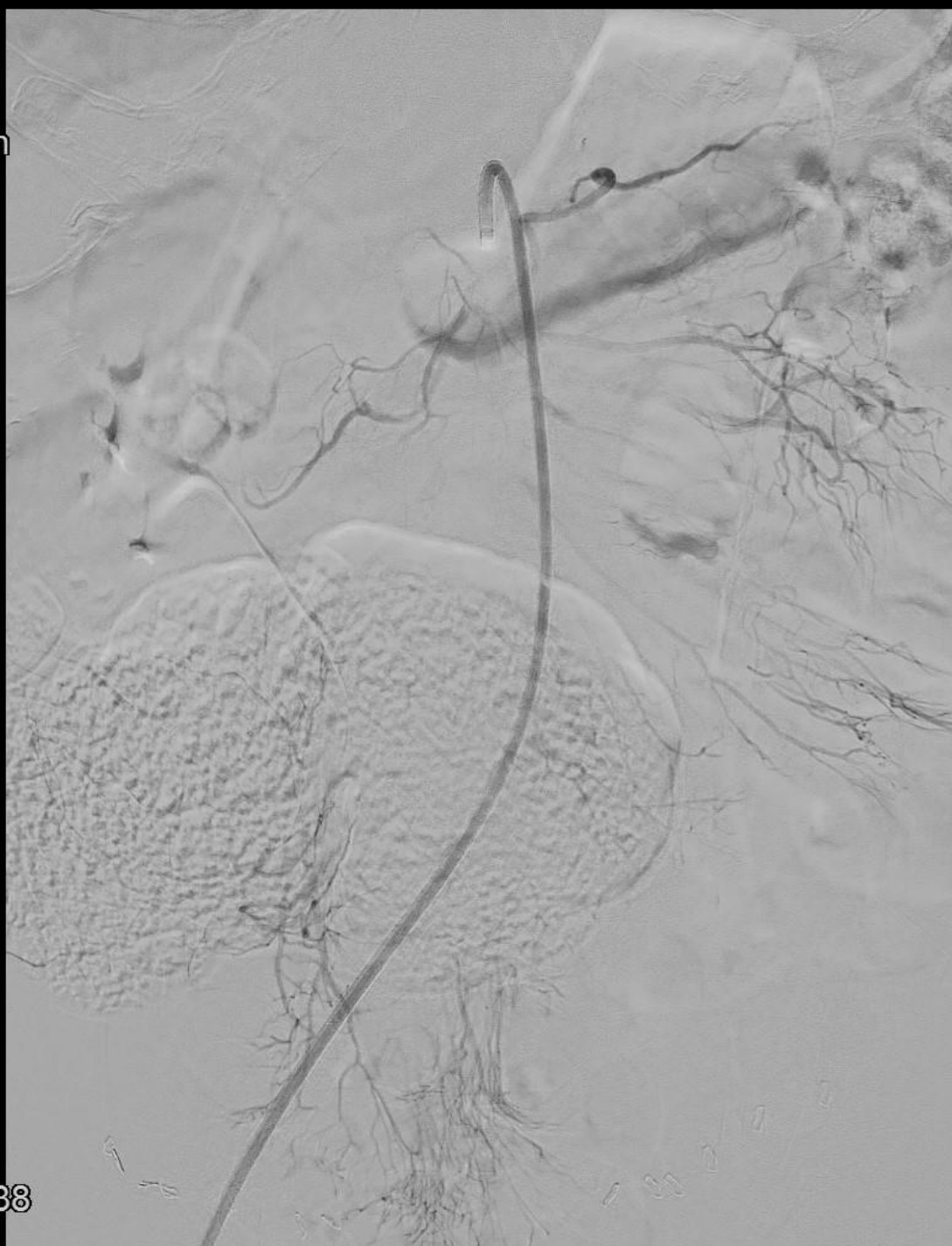Rot -2°
Ang -0°
FD 48 cm



1:50
2:50
23:28:38

6
4-6

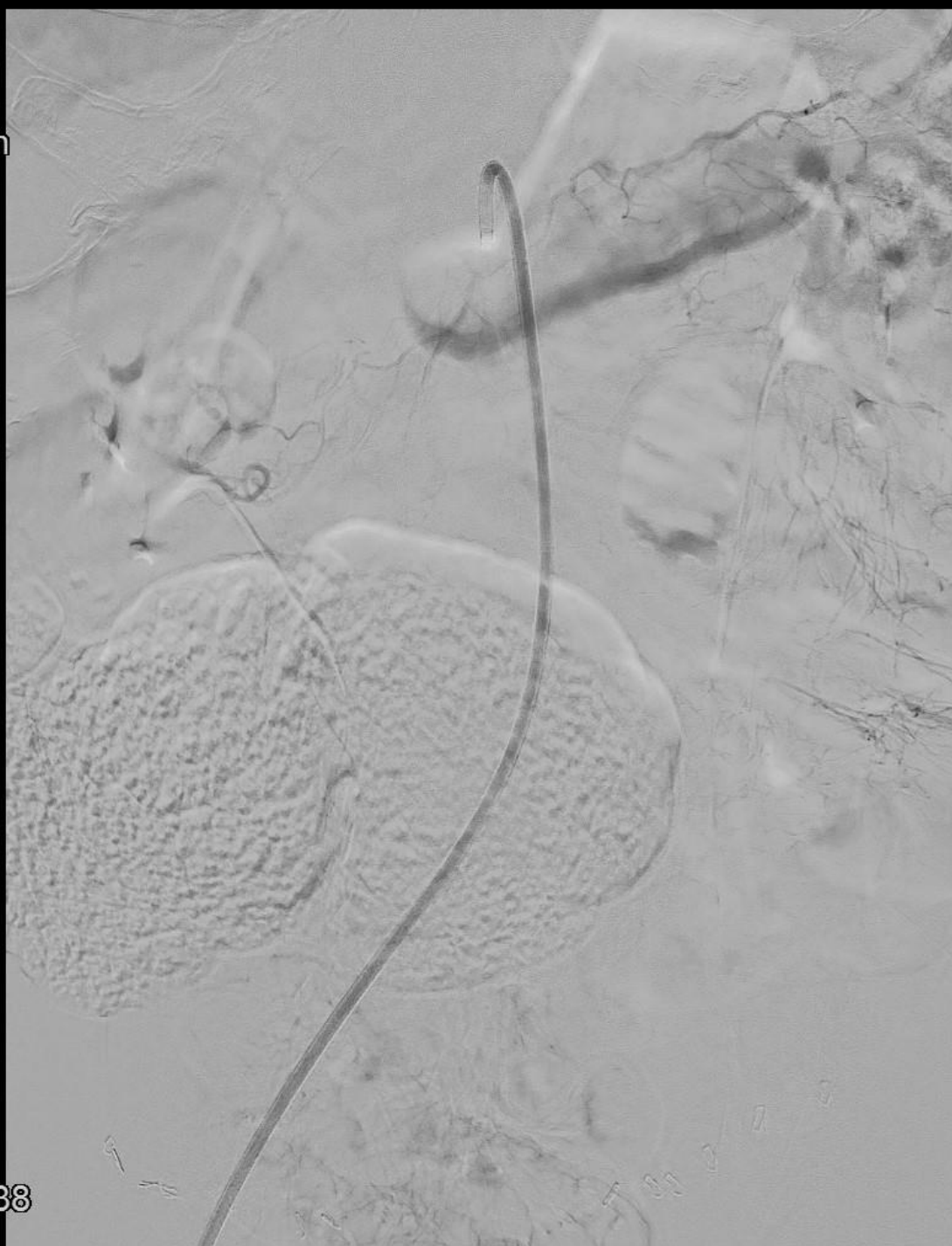
Rot -2°
Ang -0°
FD 48 cm



📄 1:50
🕒 3:00
⏮ 23:28:38

6
4-7

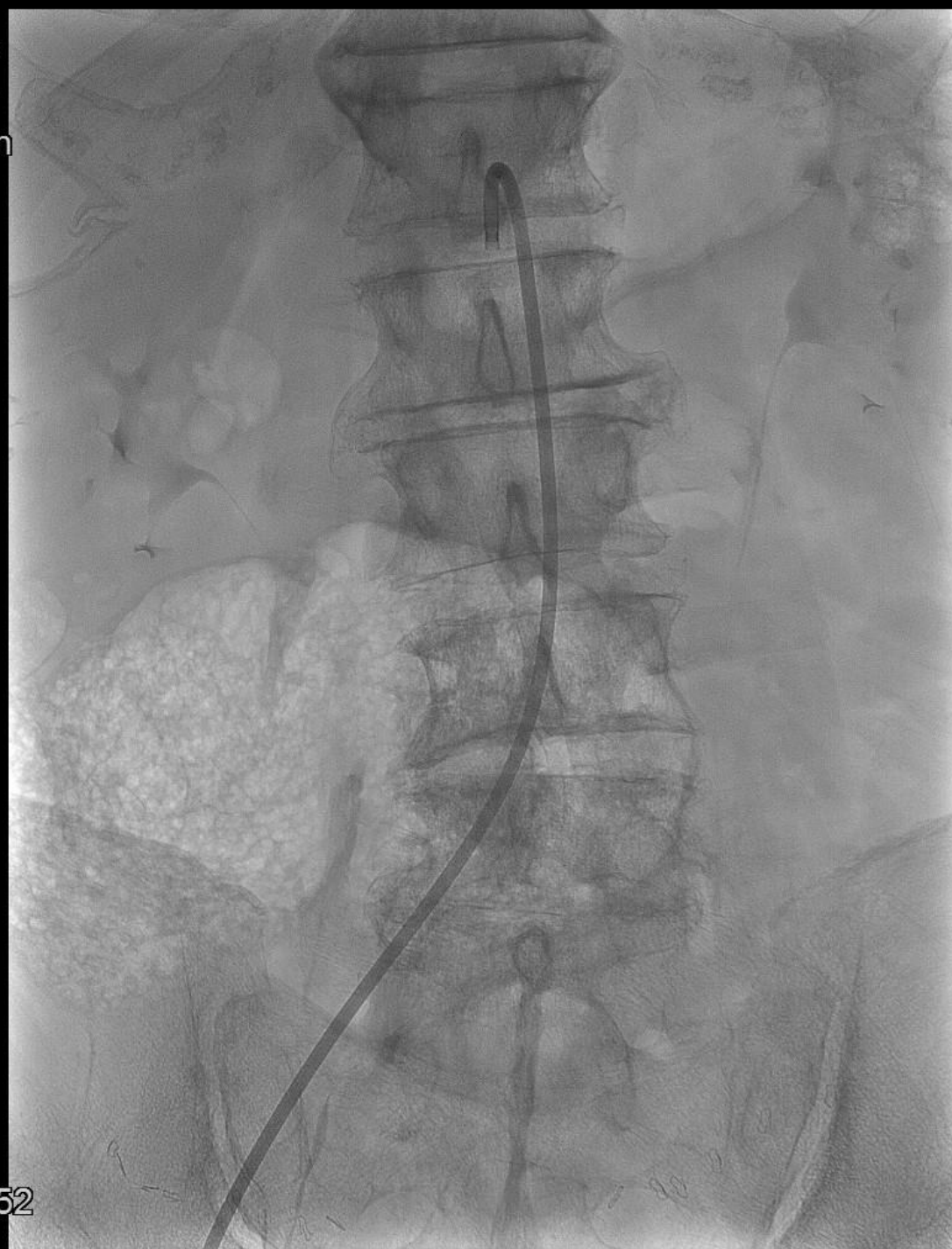
Rot -2°
Ang -0°
FD 48 cm



📄 1:50
📄 3:50
⏮ 23:28:38

6
4-8

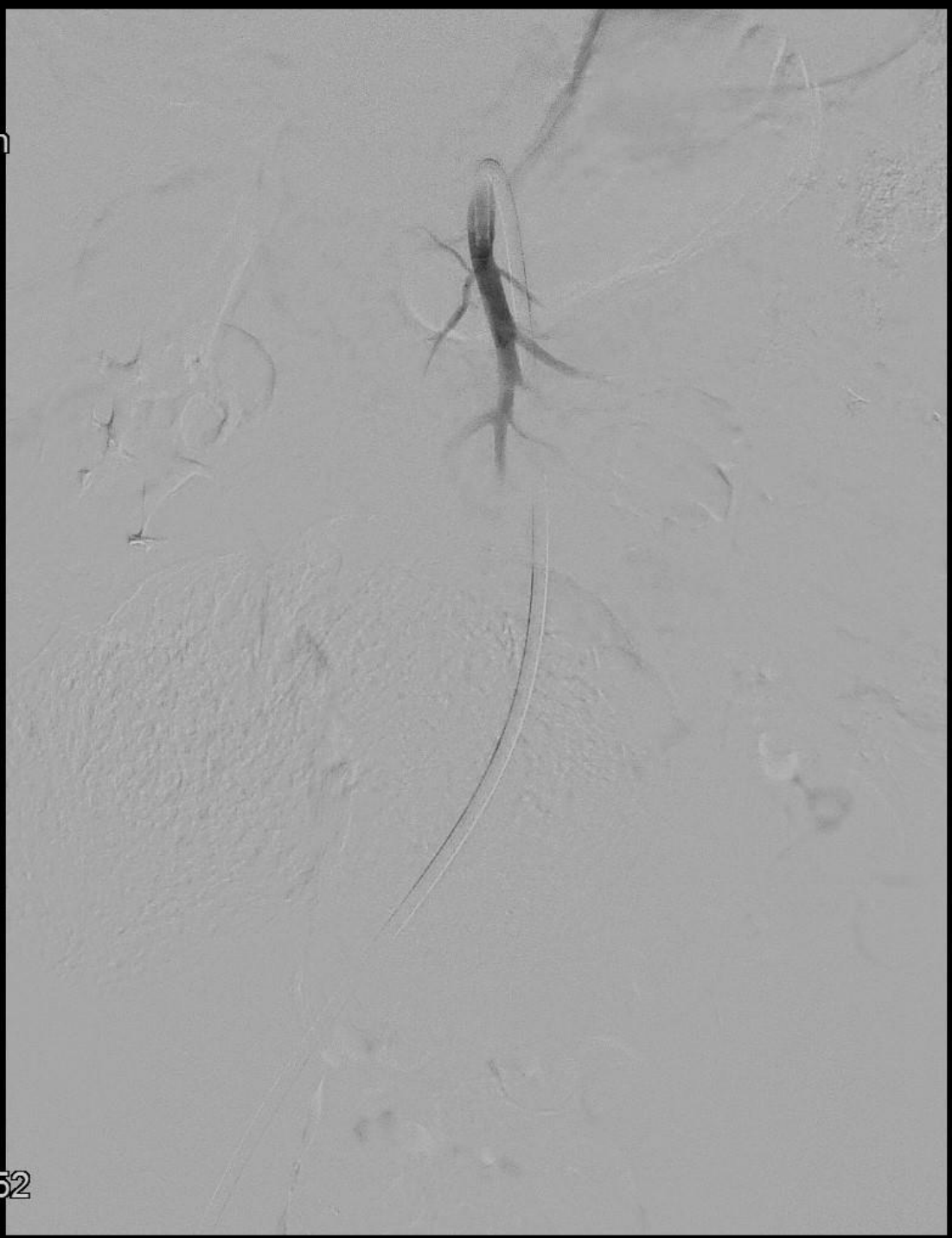
Rot -2°
Ang -0°
FD 48 cm



□ 1:00
▶▶ 23:28:52

7
3

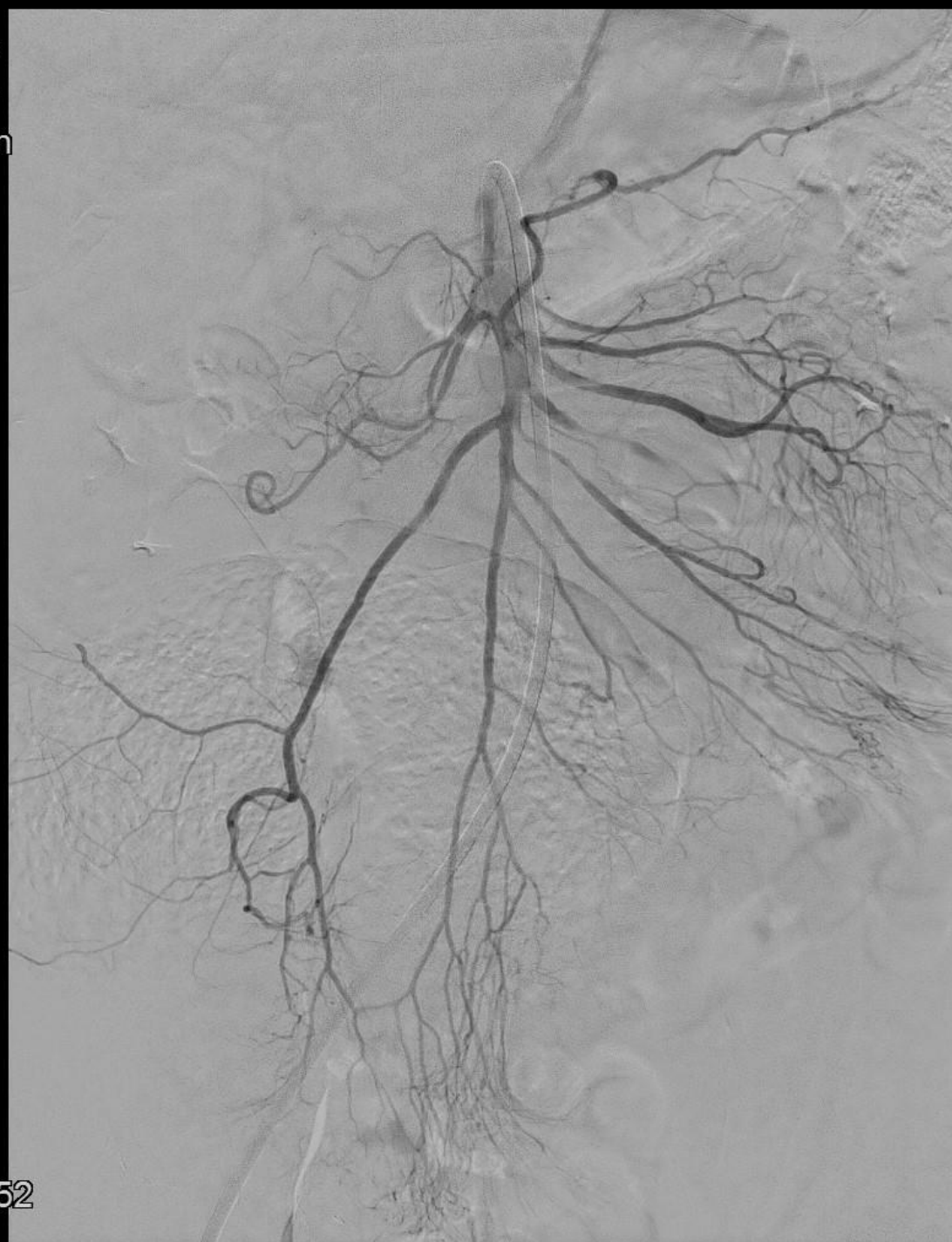Rot -2°
Ang -0°
FD 48 cm



📄 1:00
🕒 1:50
⏮ 23:28:52

7
3-4

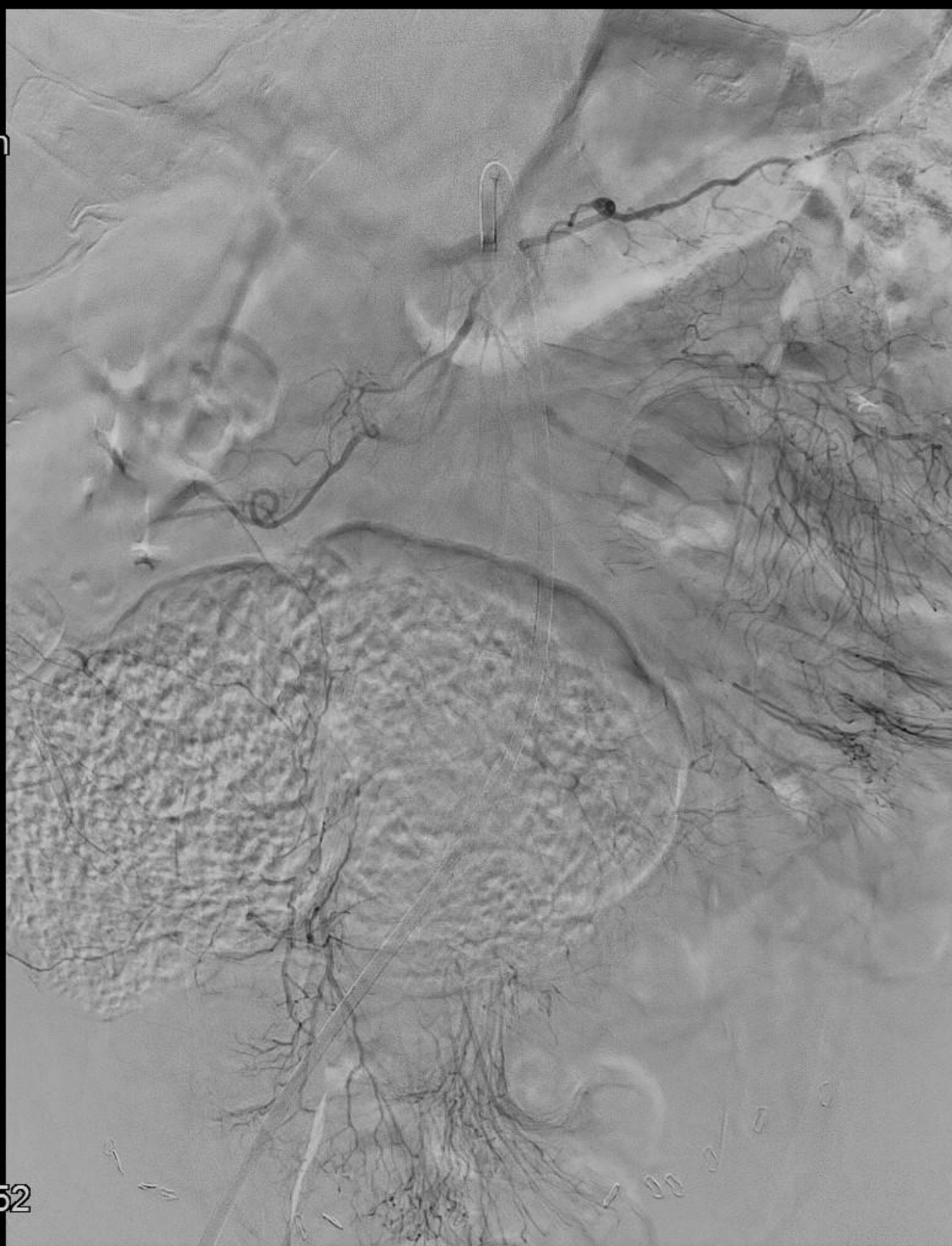
Rot -2°
Ang -0°
FD 48 cm



📄 1:00
🕒 2:50
⏮ 23:28:52

7
3-6

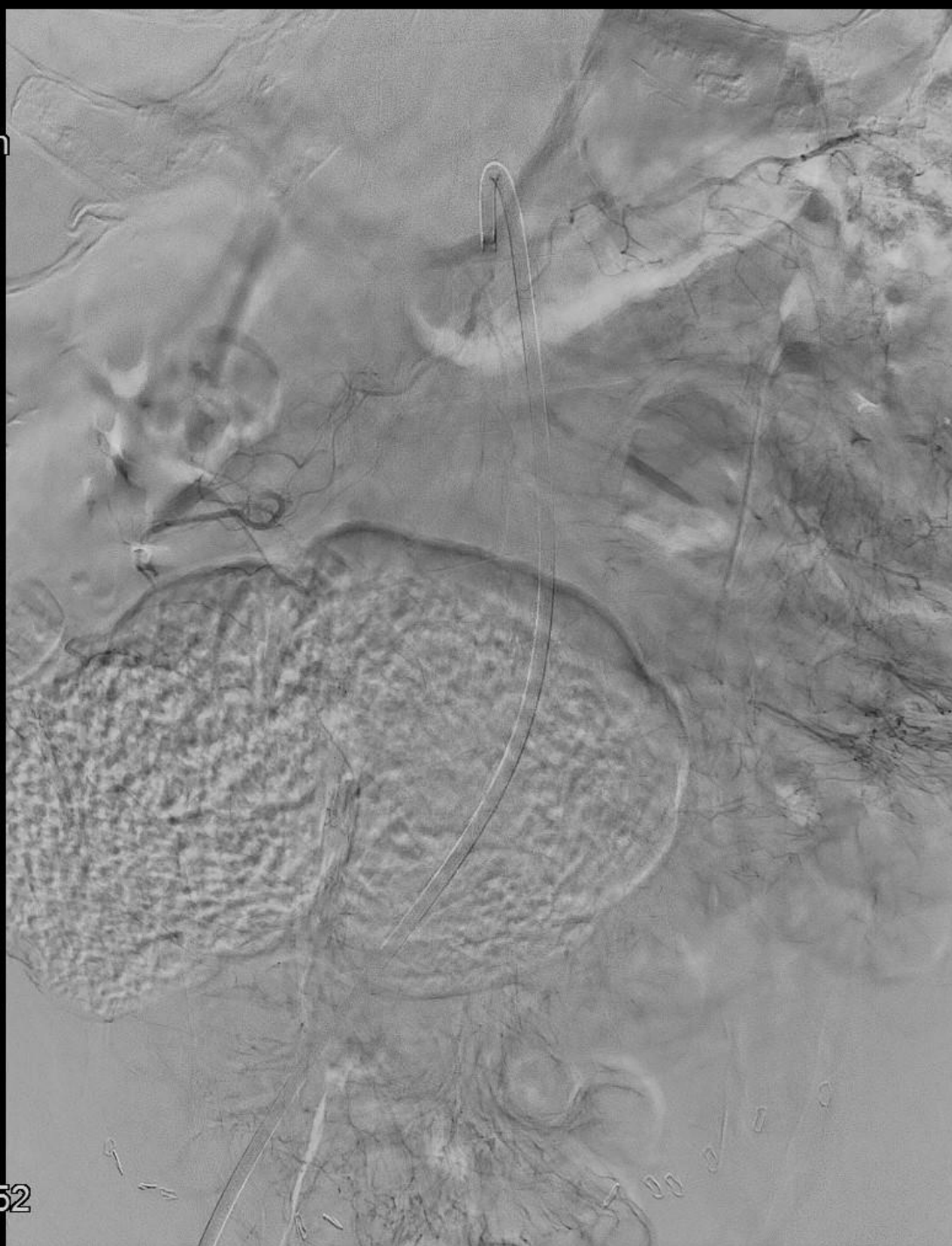
Rot -2°
Ang -0°
FD 48 cm



📏 1:00
🕒 3:00
⏮ 23:28:52

7
3-7

Rot -2°
Ang -0°
FD 48 cm



📄 1:00
🕒 3:50
⏮ 23:28:52

7
3-8

Post embolektomi

- Grundet fortsat abdominalt ubehag -> laporatom
 - Fund af vitale tarme
 - 2. look 2 dage senere – fortsat vitale tarme
 - Lukning af abdomen.

Tak