

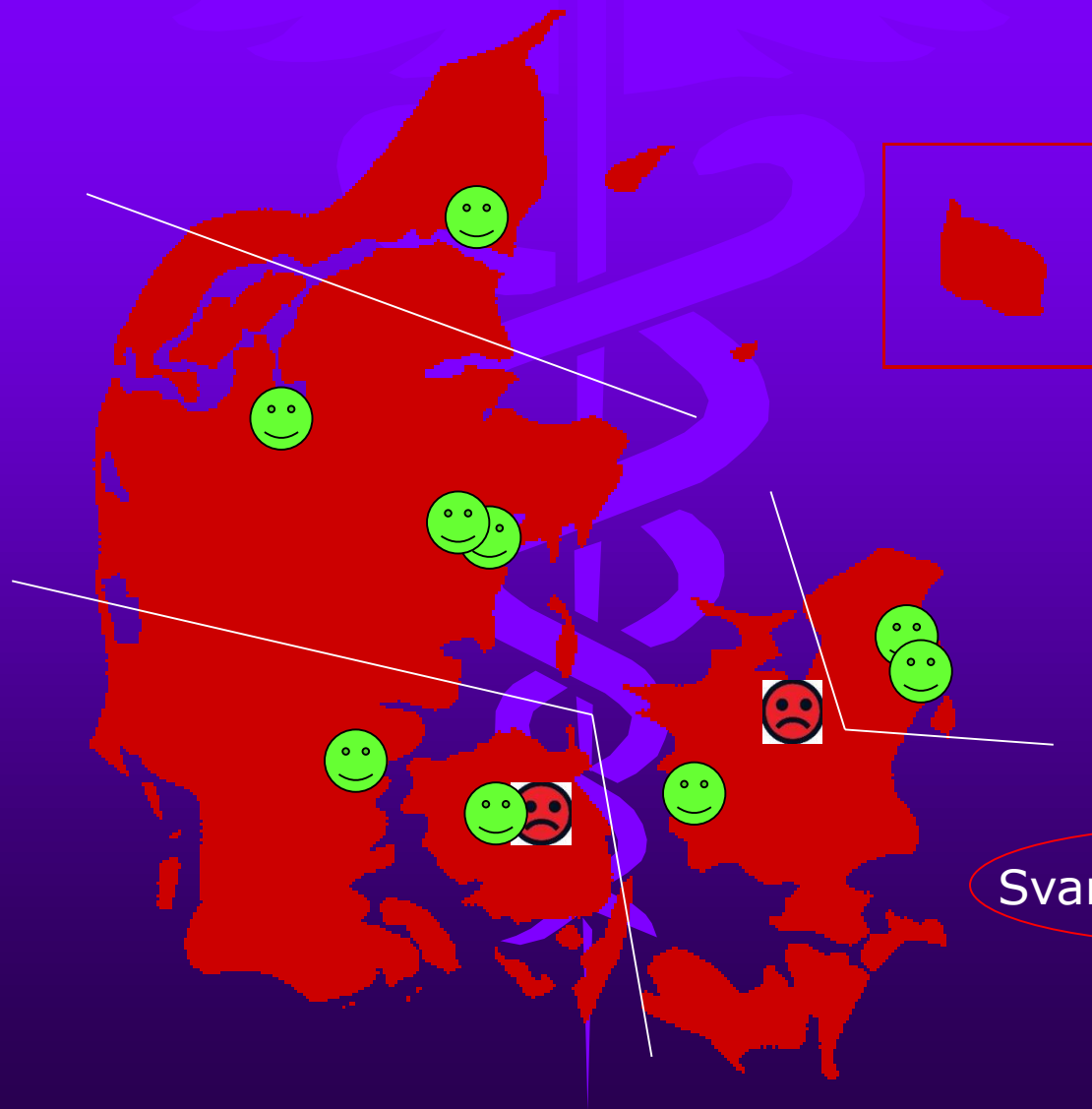
Enqueten 2019

DFIR

Enqueten 2018

PROCEDURE	ANTAL
PTA:	
- Iliaca	_____
- Femoralis + poplitea	_____
- Below the knee	_____
- By-pass grafter	_____
EVAR	_____
TEVAR	_____
Centrale vener	_____
Hæmodialysefistler	_____
PTC	_____
TIPSS	_____
TIPSS sek. interv.	_____
Tumorablation (angiv tumortype):	
- Cryo	_____
- RF	_____
Nefrostomier	_____
Ureterostomier	_____
Embolisering:	
- UFE	_____
- GI-kanal	_____
- Traume	_____
- Tumor, præ-OP mhp. hæmostase	_____

Afdelinger 2018



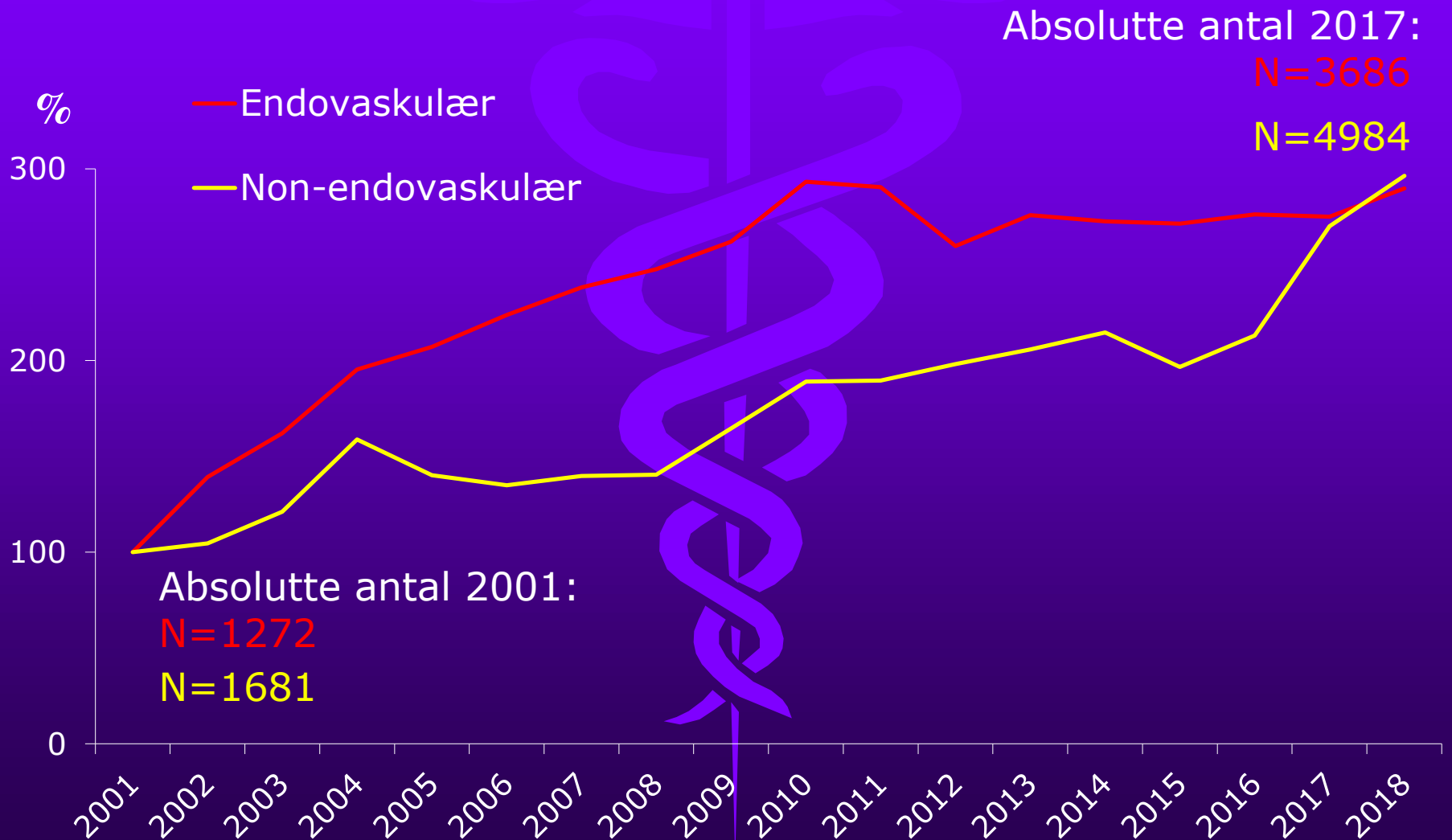
Svar procent: 81%

Intervention

- Arteriesystemet
- Hemodialysefistler
- GI-kanalen
- Lever/galdeveje
- Urinveje
- Embolisering

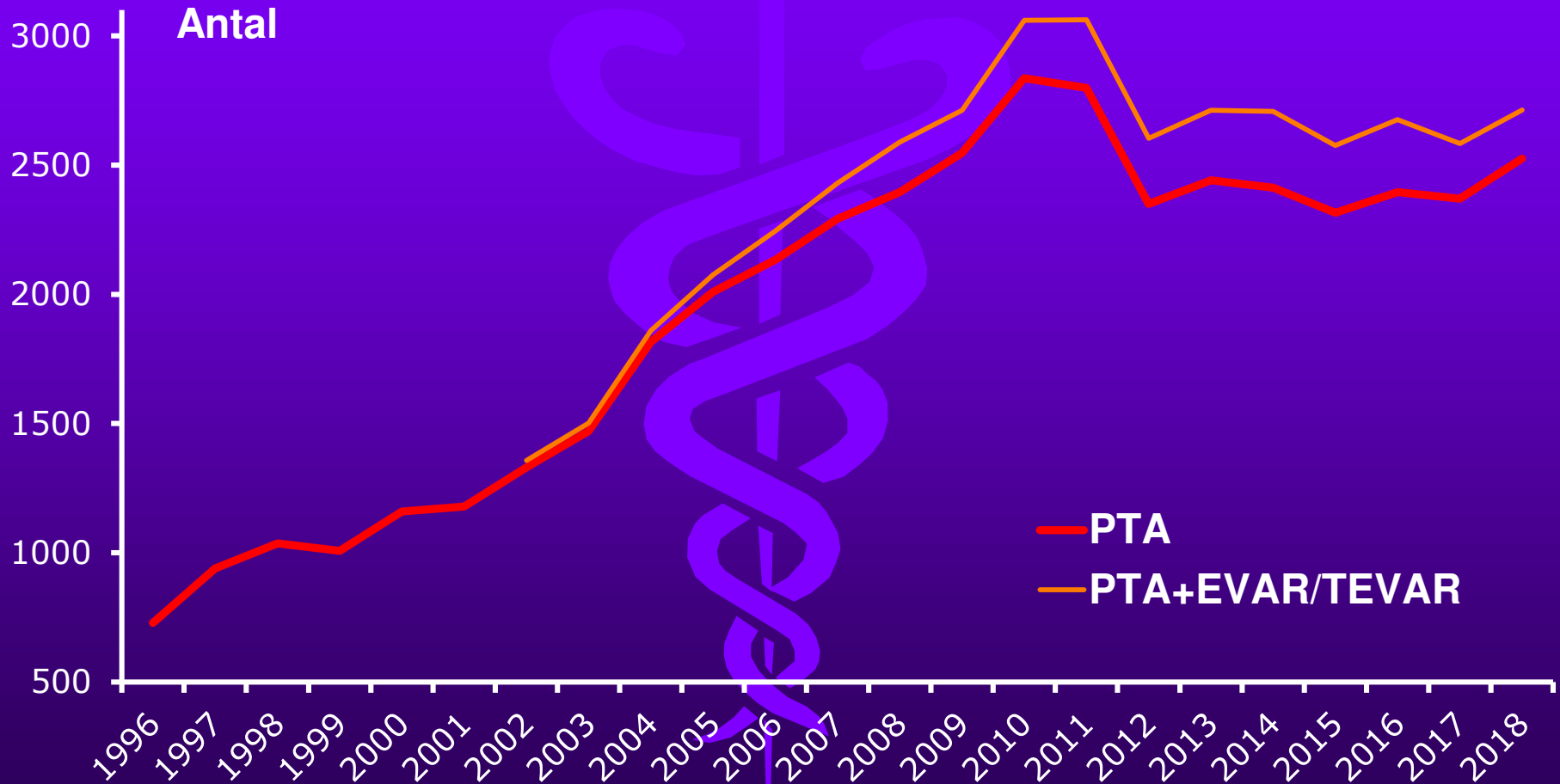
Aktivitetsudvikling

Hele landet

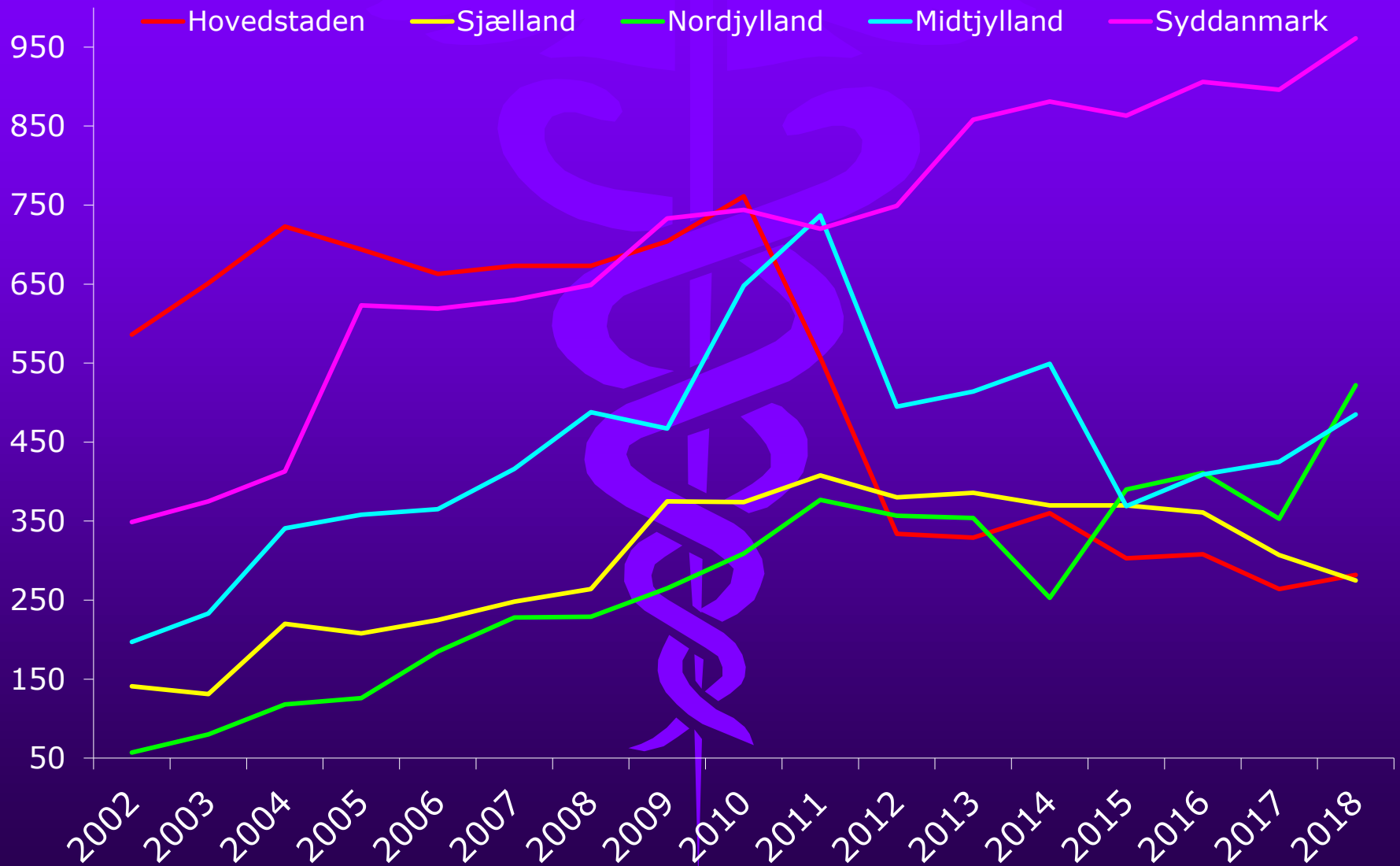


PTA 1996-2018

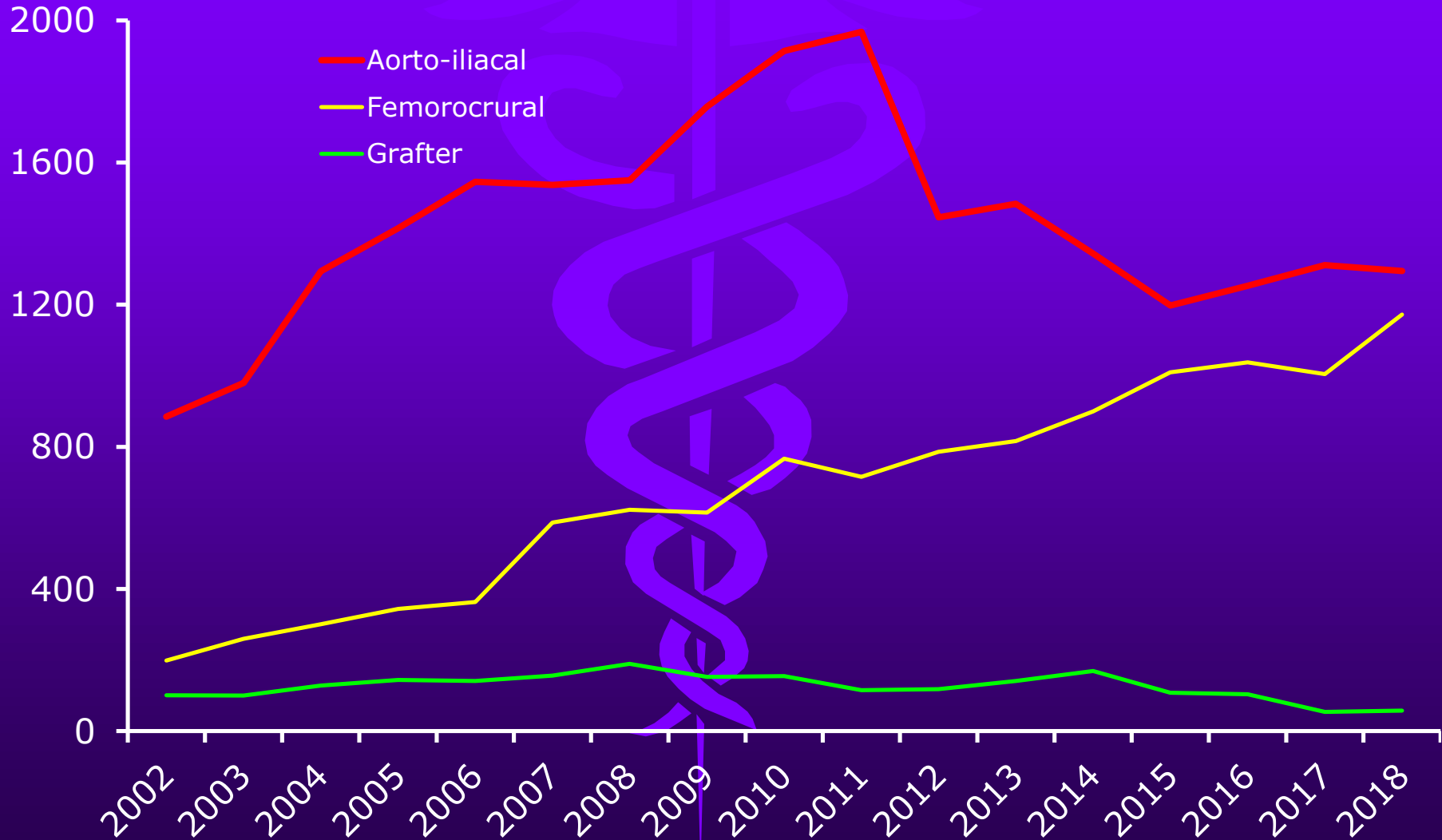
(stentgraftanlæggelse ikke medregnet)



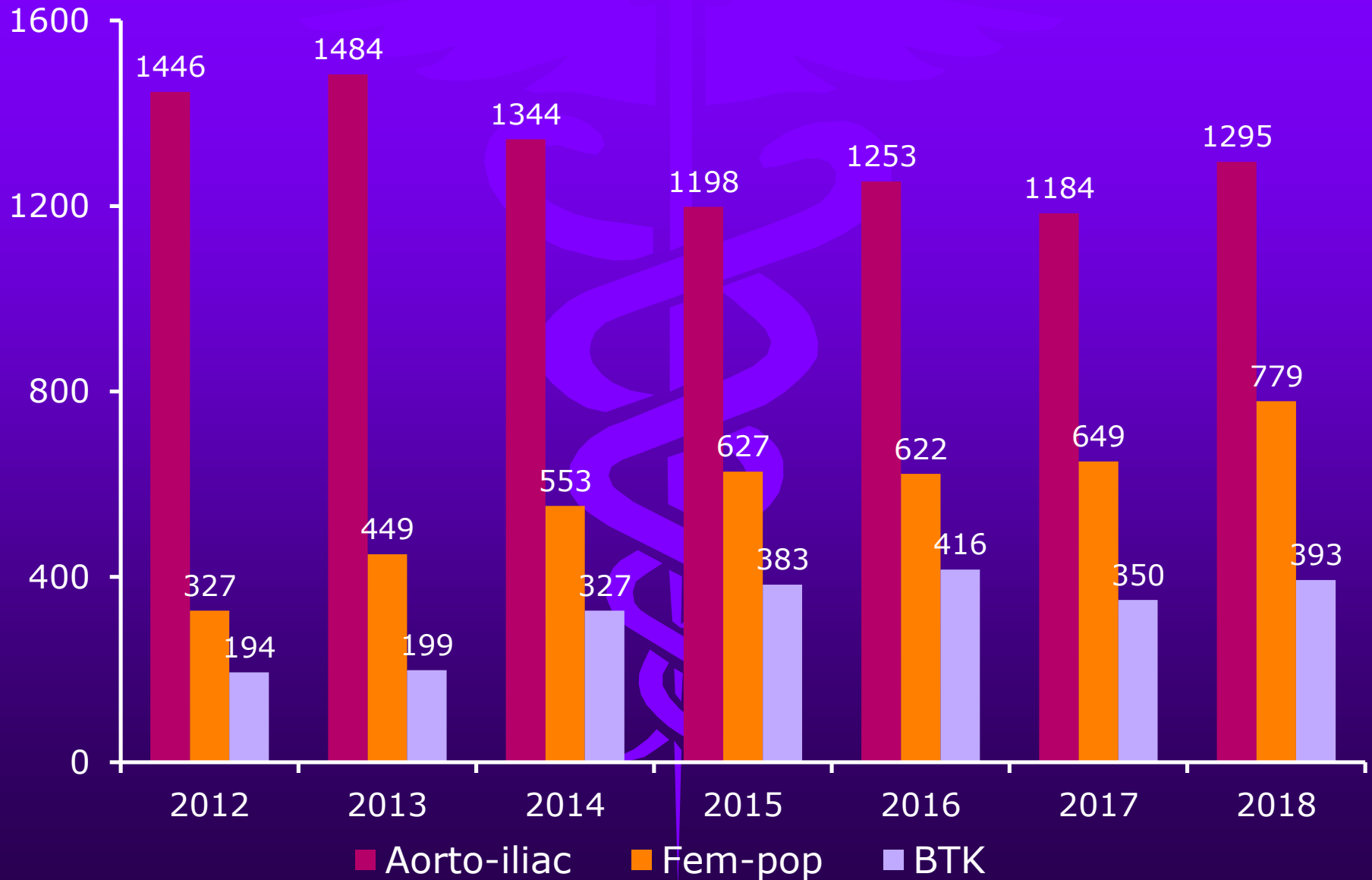
PTA – Regioner 2002-2018



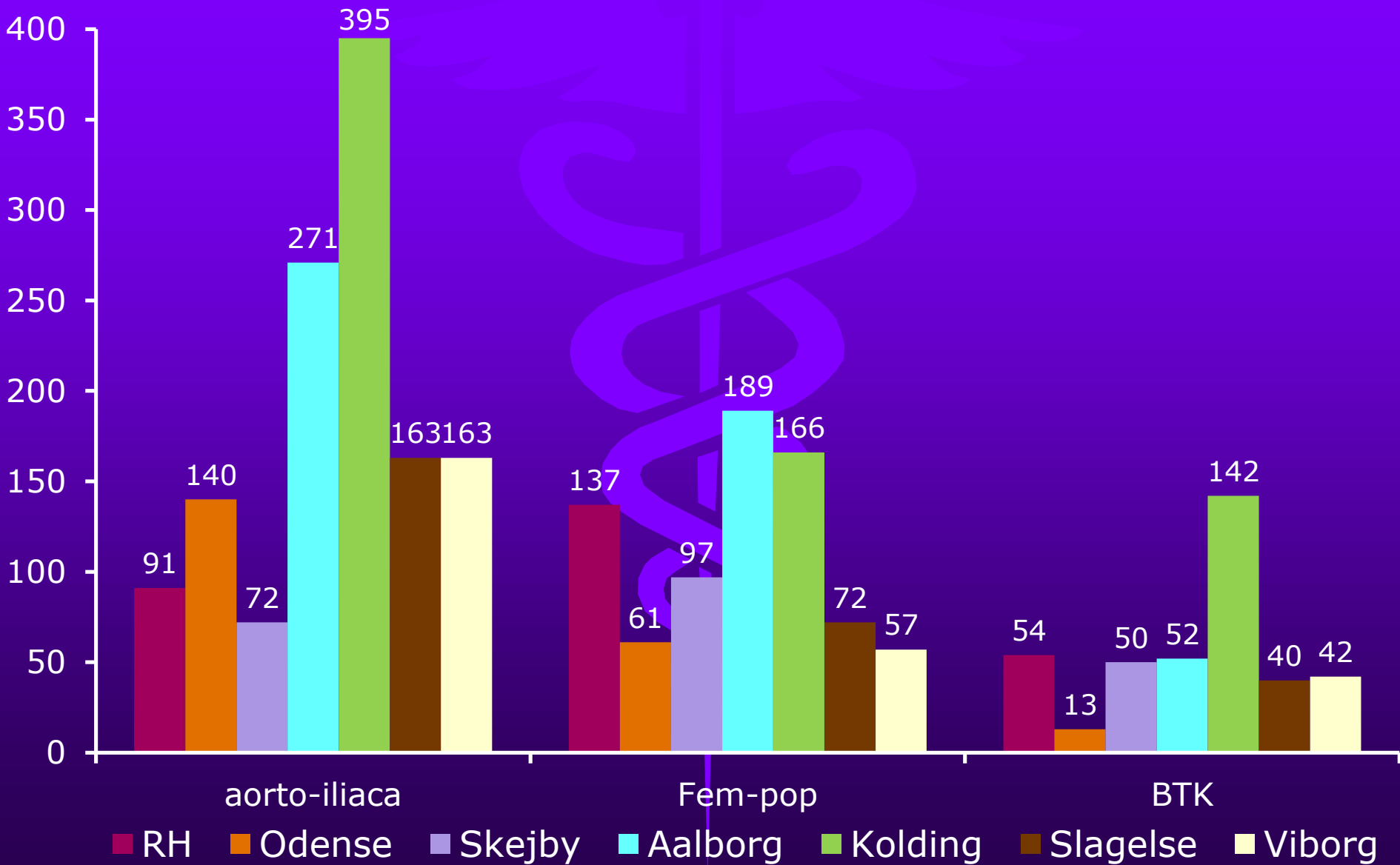
PTA 2002-2018



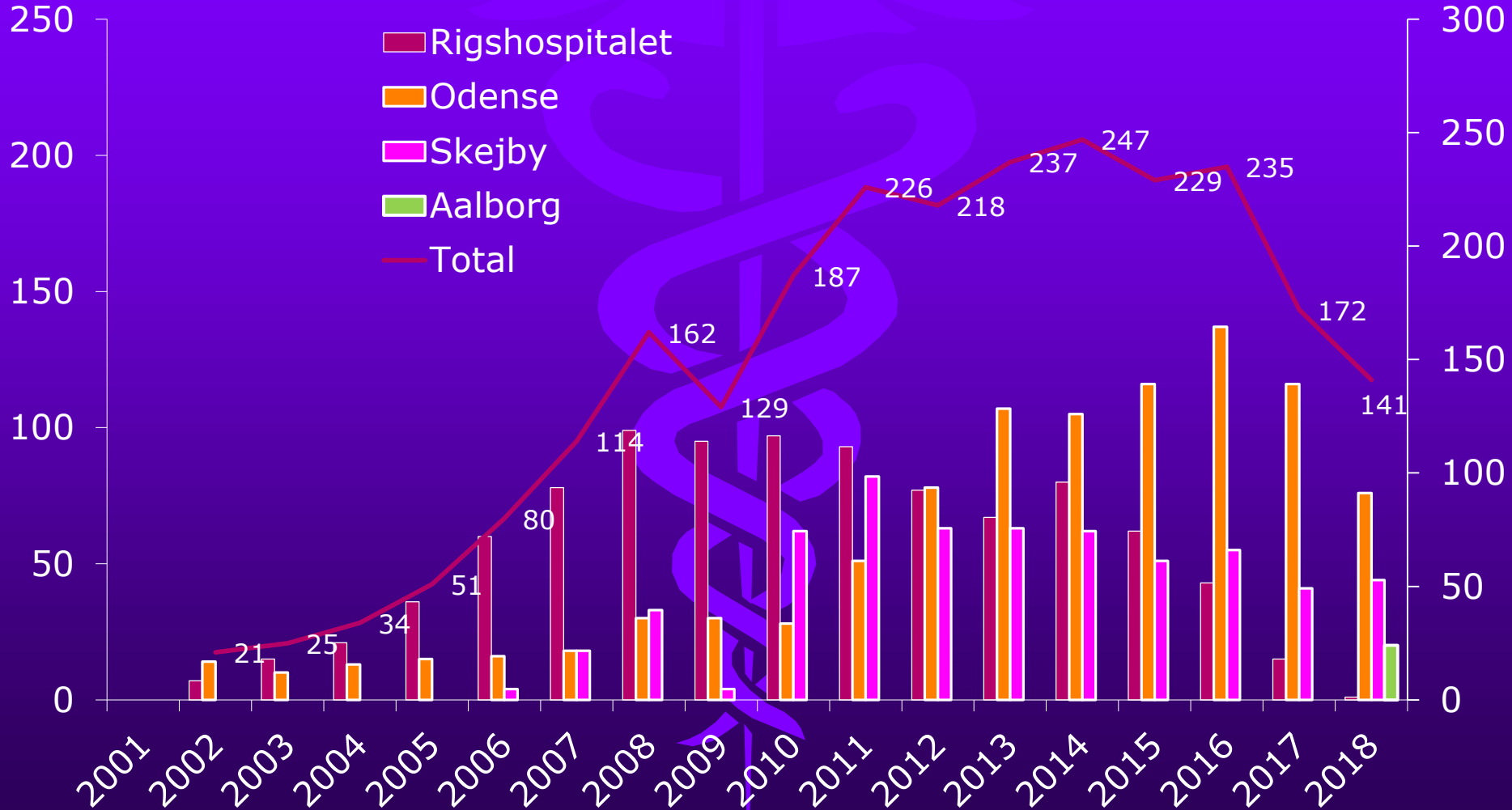
PTA 2012-2018



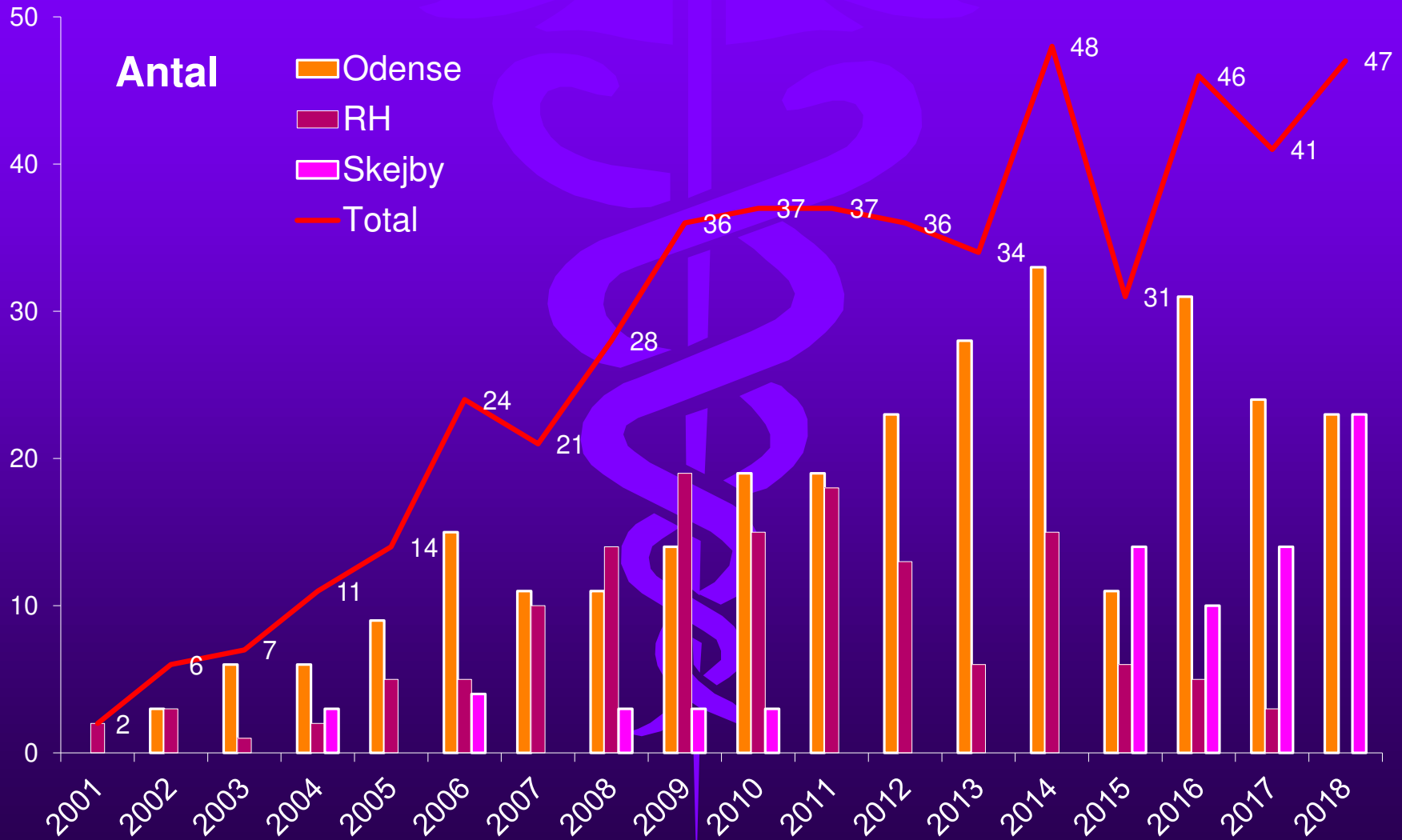
PTA i 2018



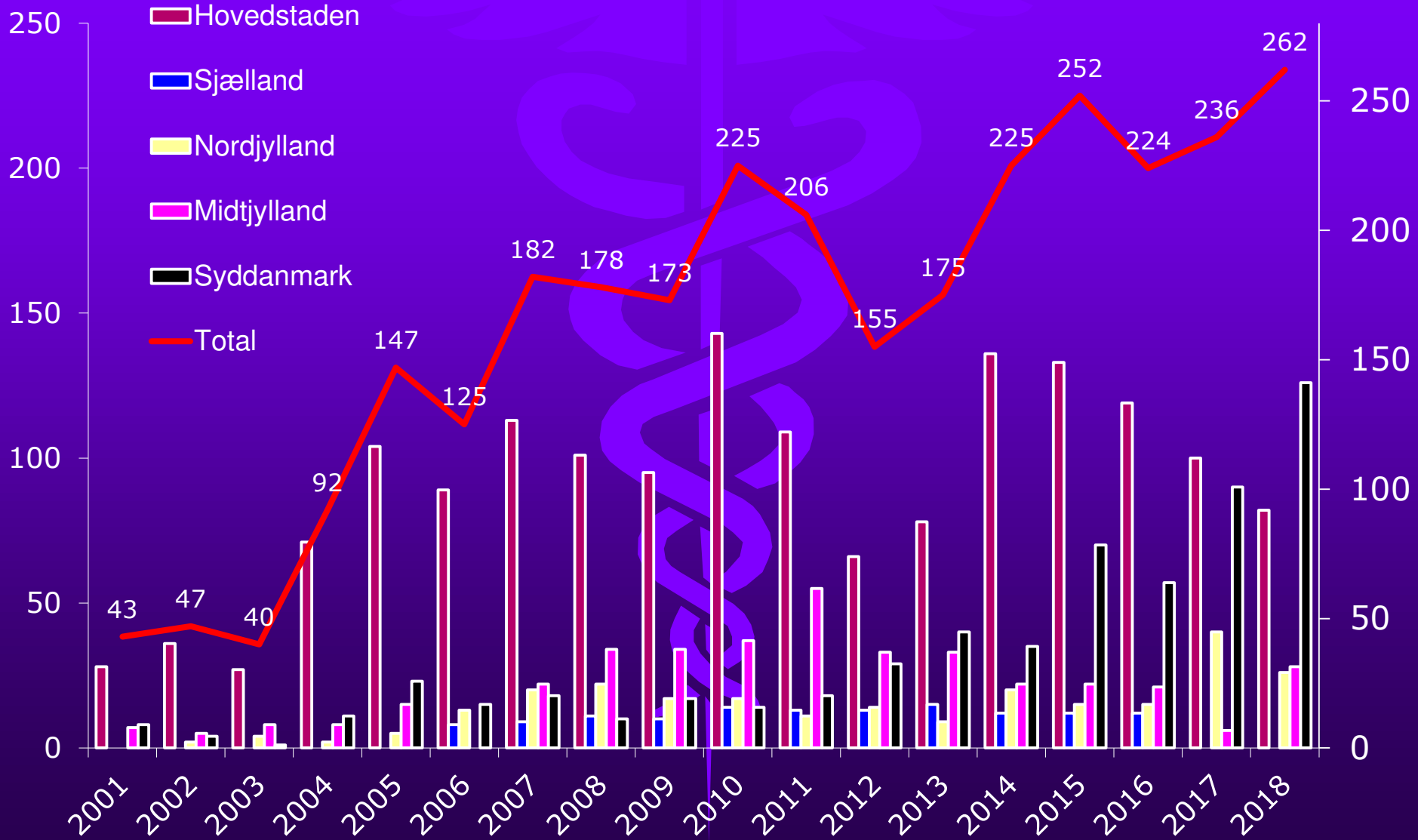
EVAR



TEVAR



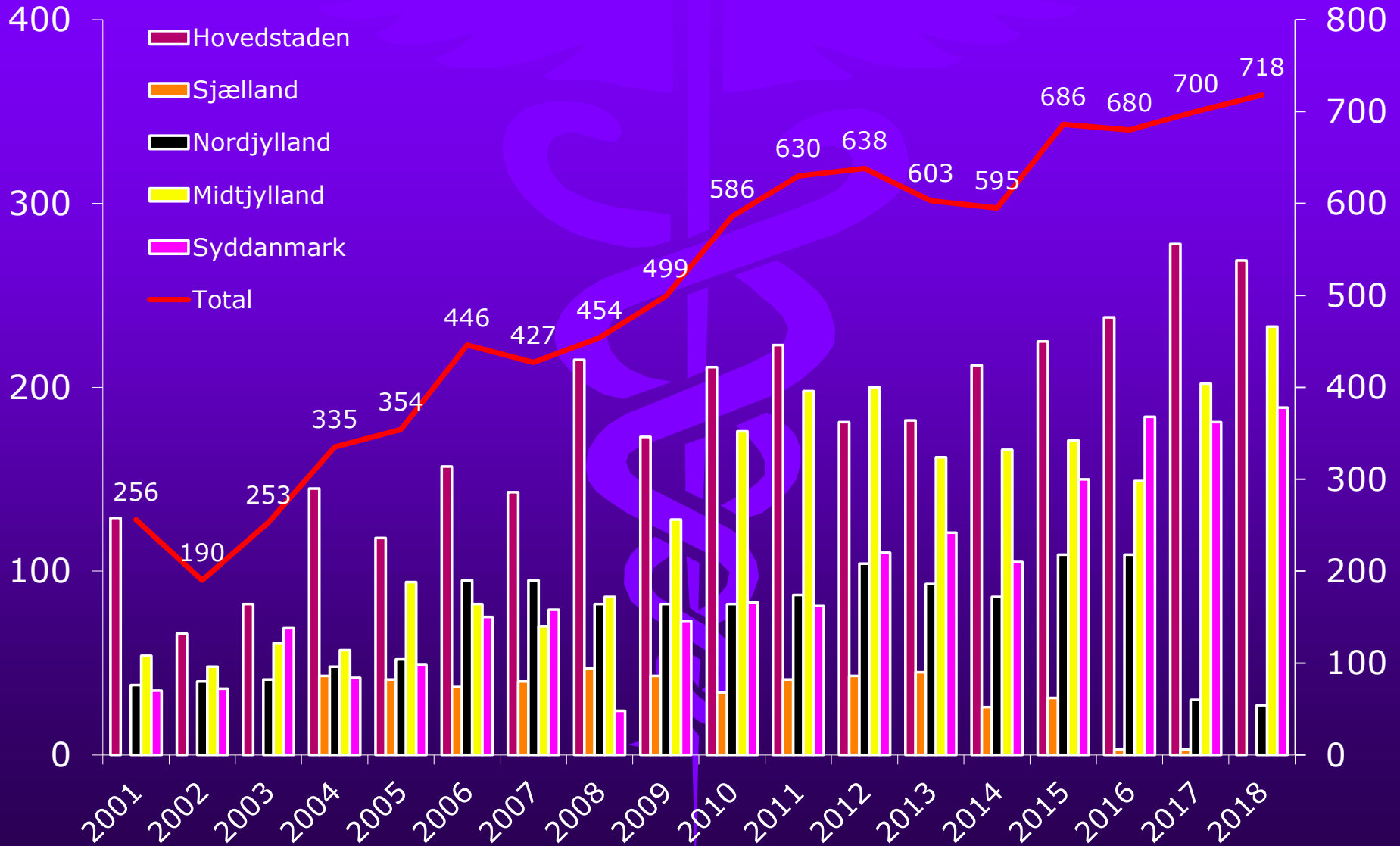
Hæmodialysefistler



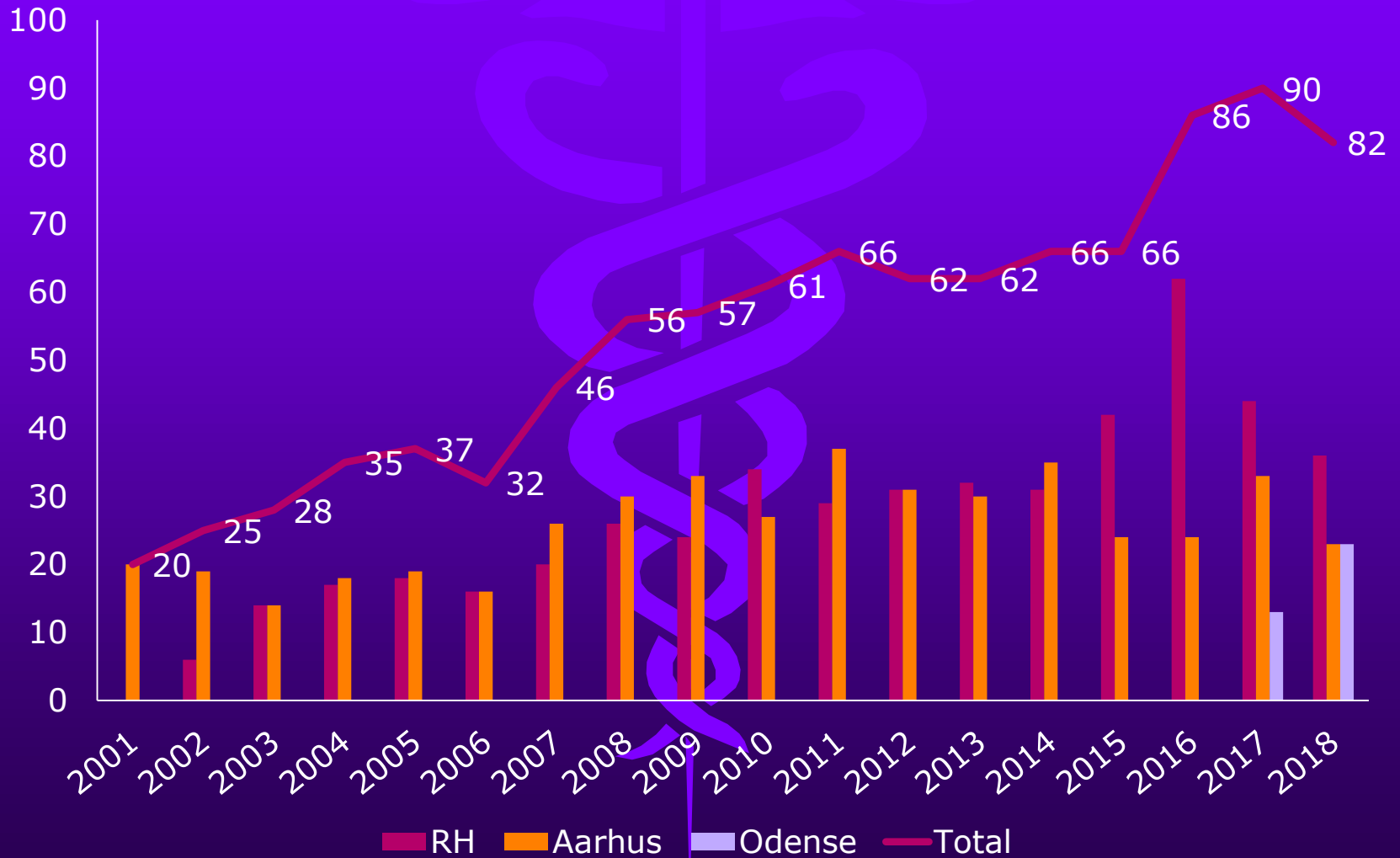
Lever/galdeveje

- PTC
- TIPS
- TIPS+ sek. intervention
- Tumorablation

PTC

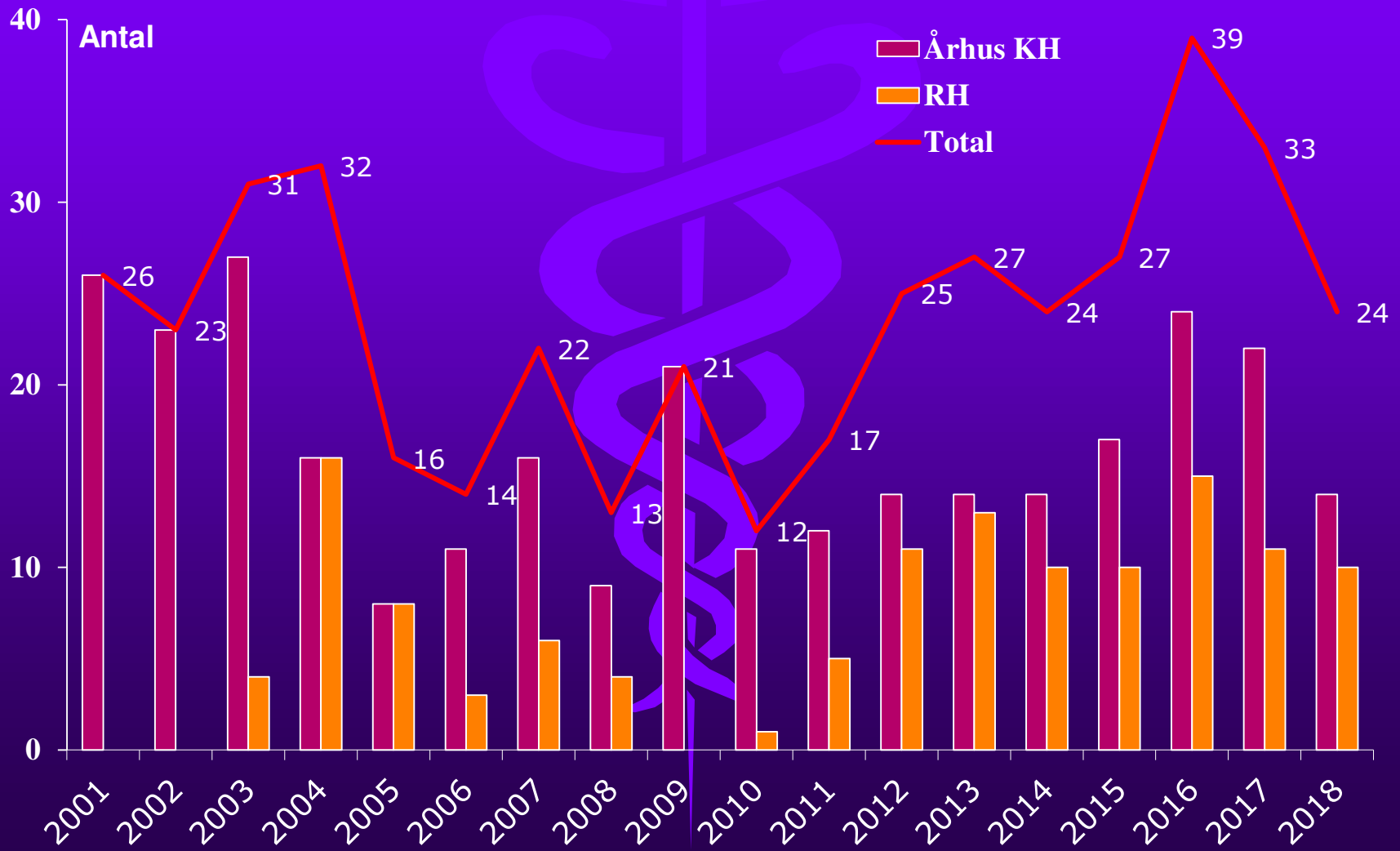


TIPS

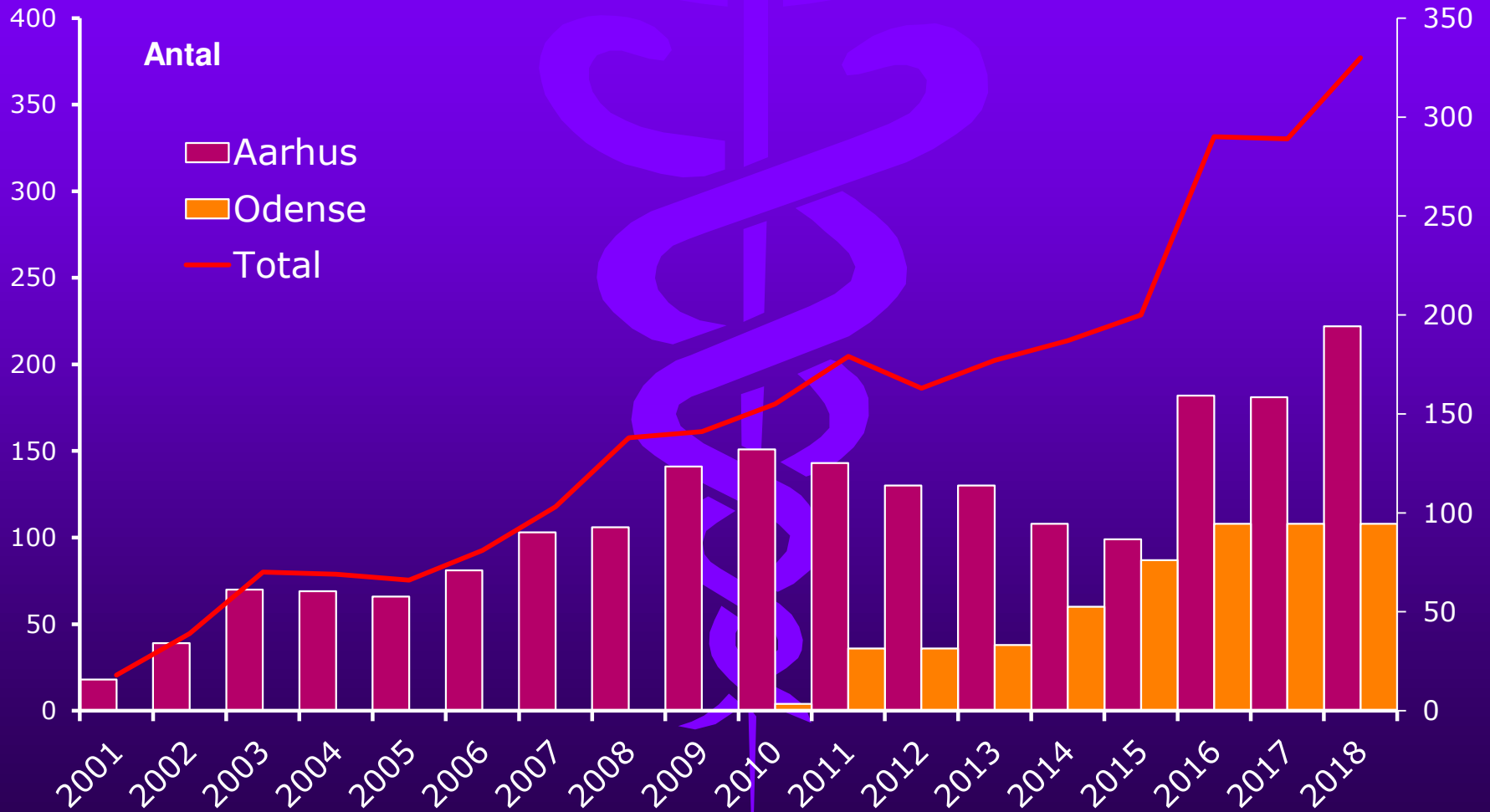


TIPS

Sek. interventioner



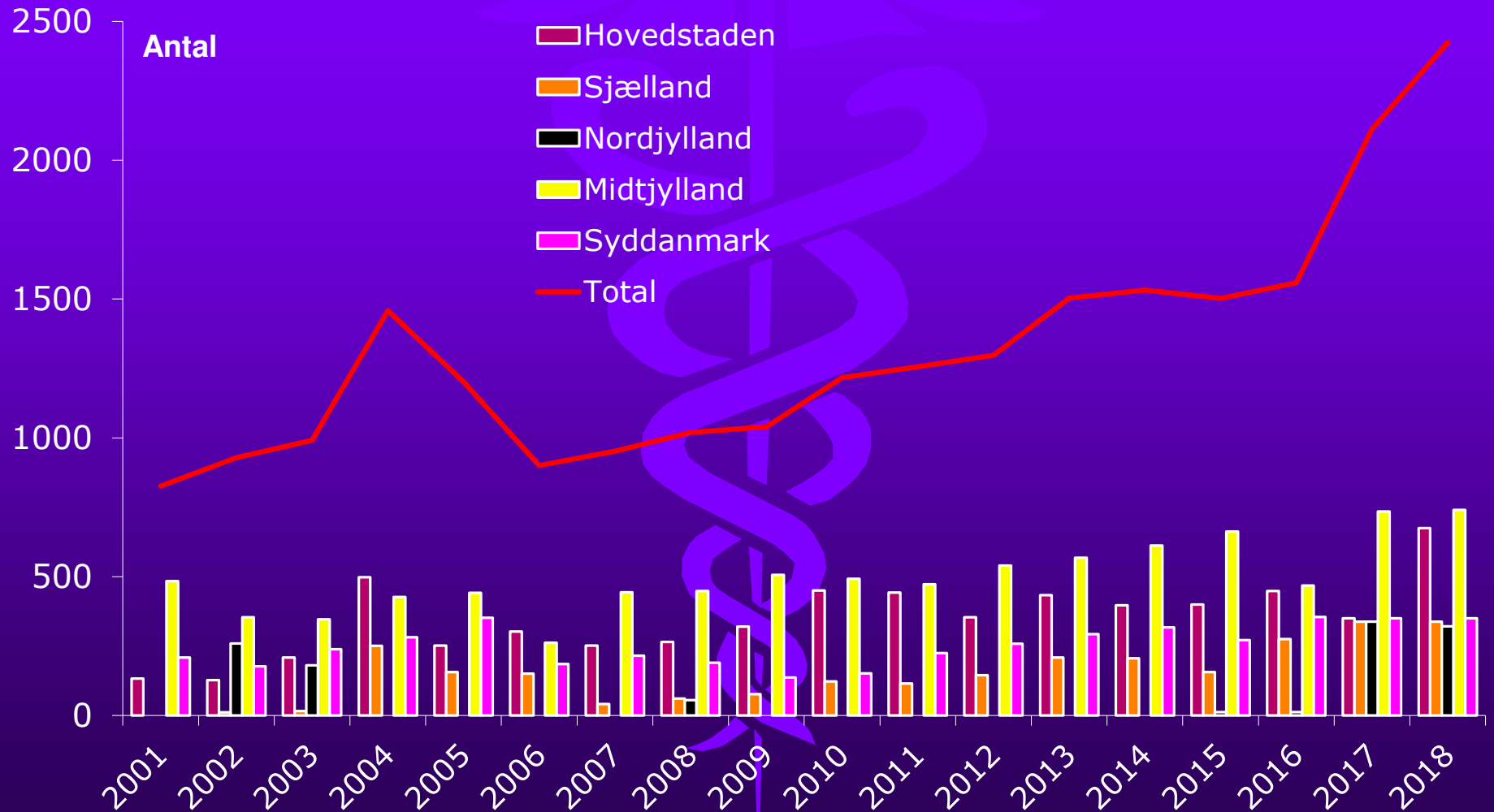
Tumor-ablation (RF/MW - lever)



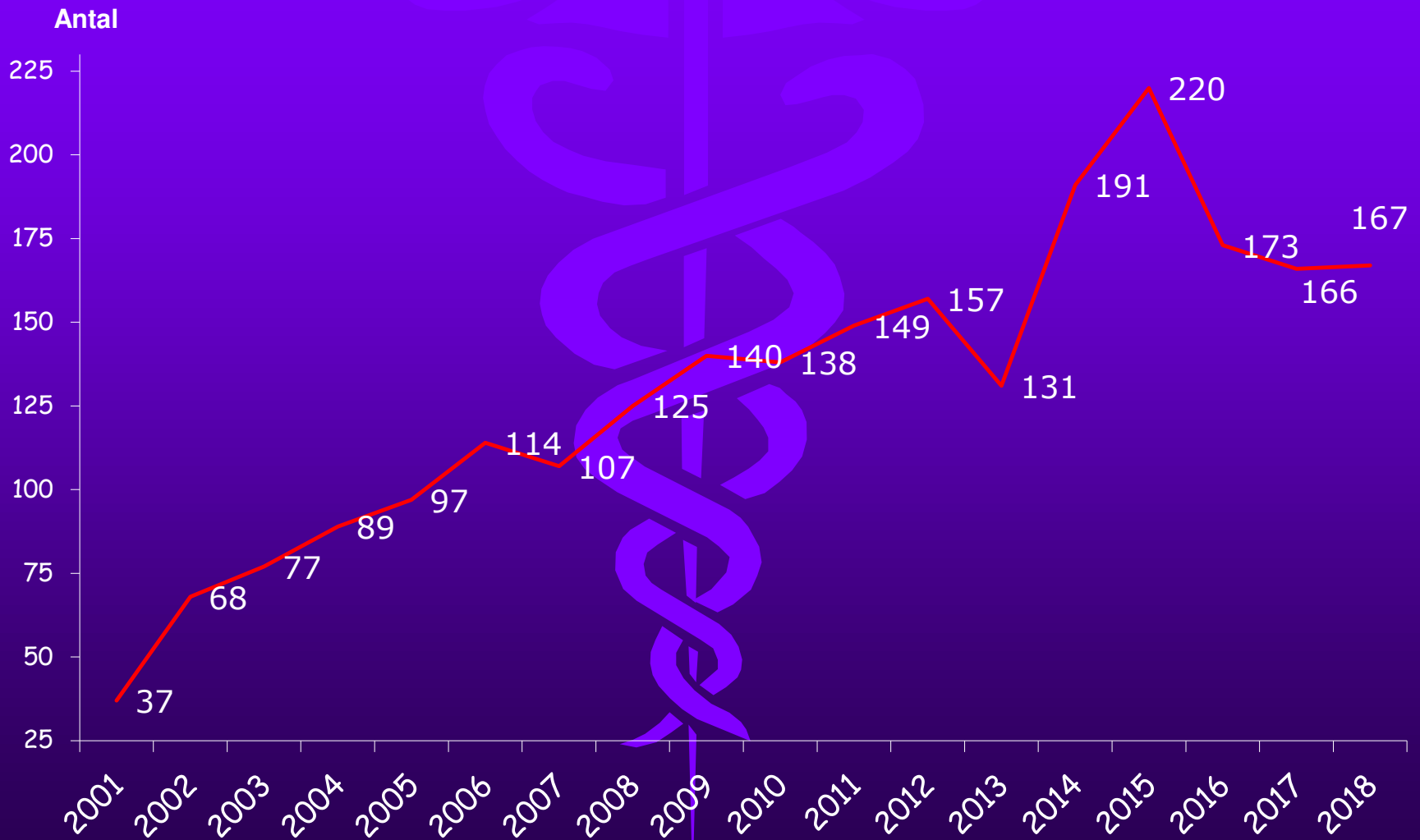
Urinveje

- Nefrostomier
- Ureterostomier/stents

Nefrostomier



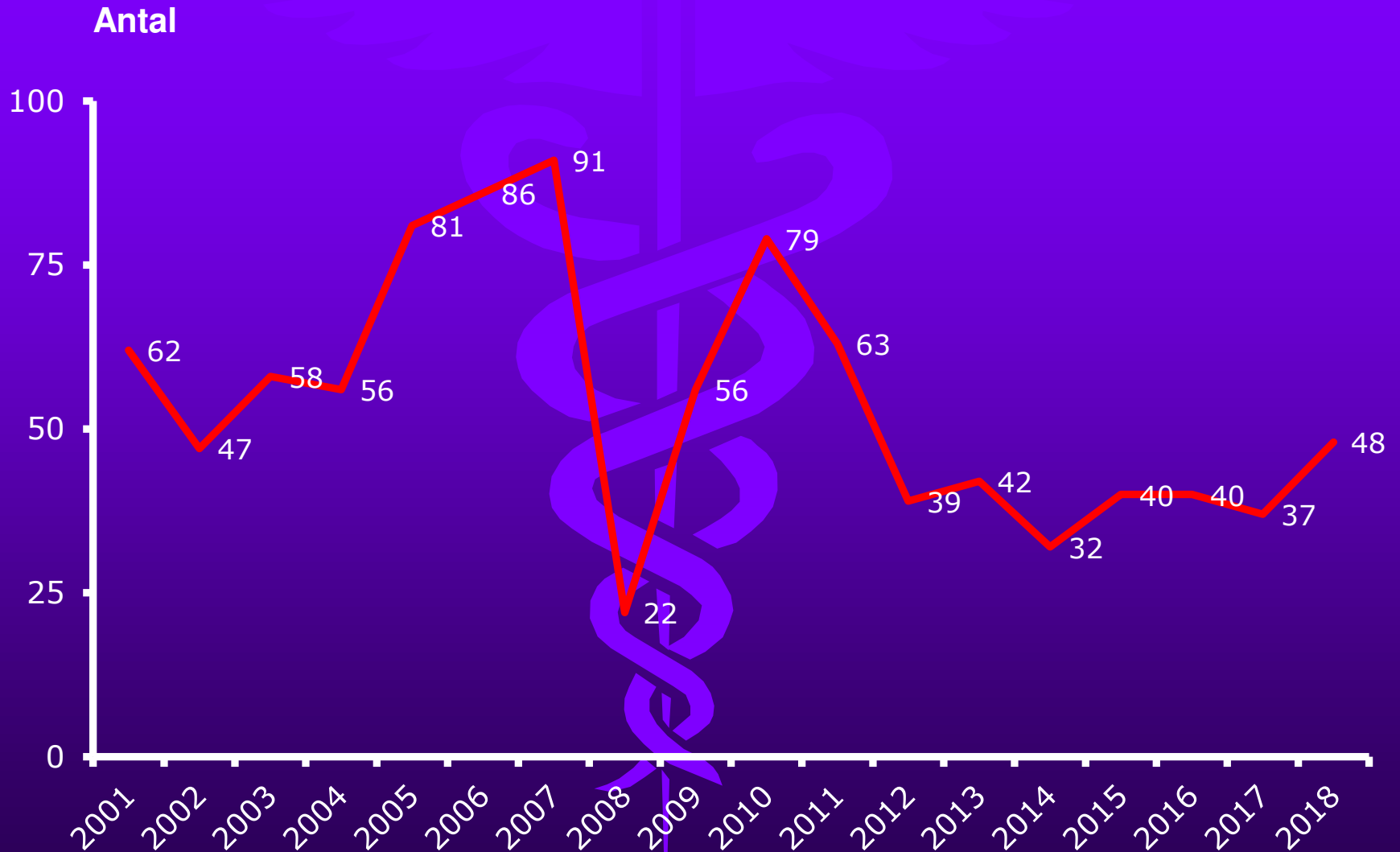
Ureterostomier/stents



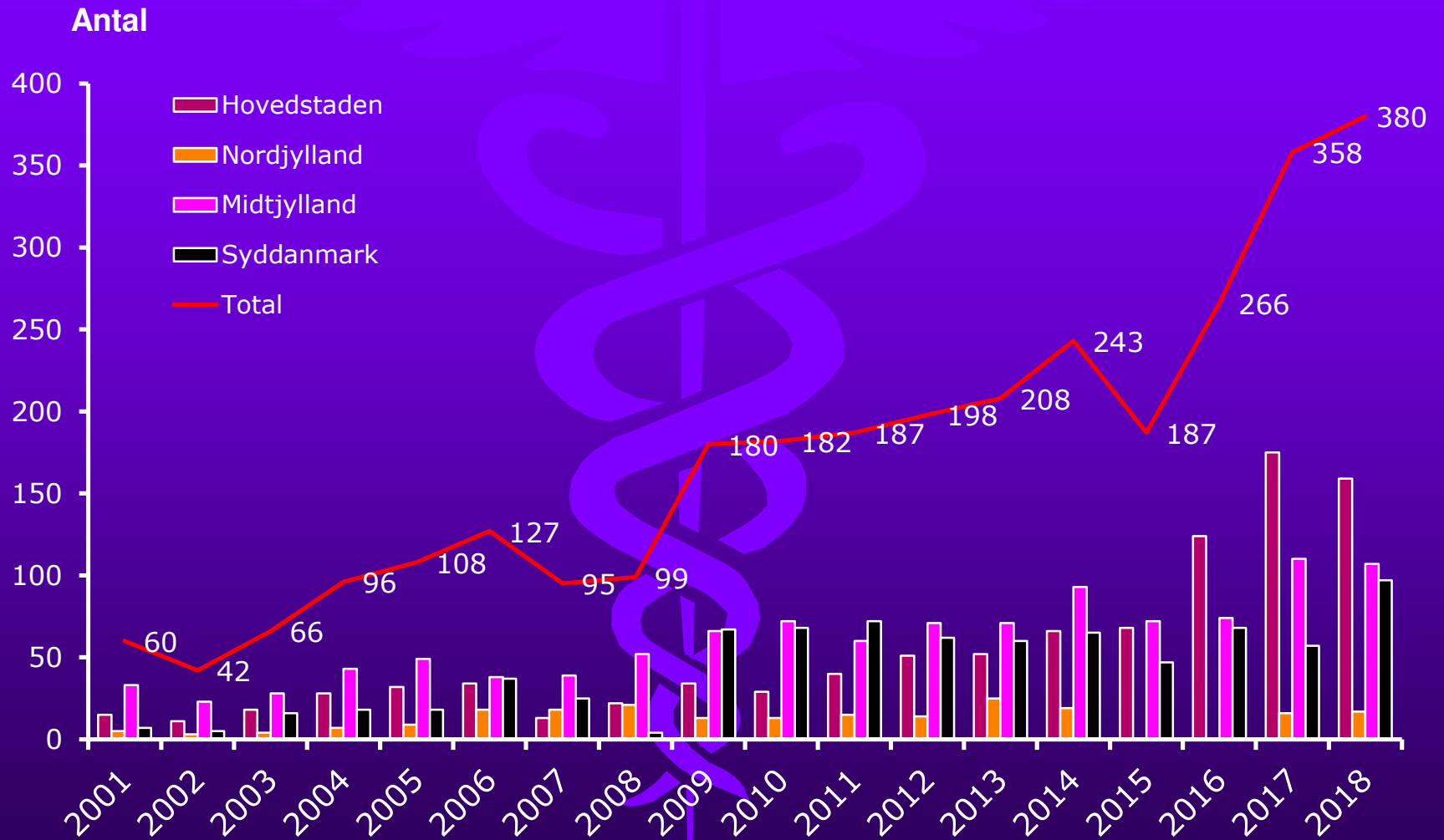
Embolisering

- Uterusfibromer
- GI-blødning
- Traumer
- Tumor embolisering
- Kemo-embolisering

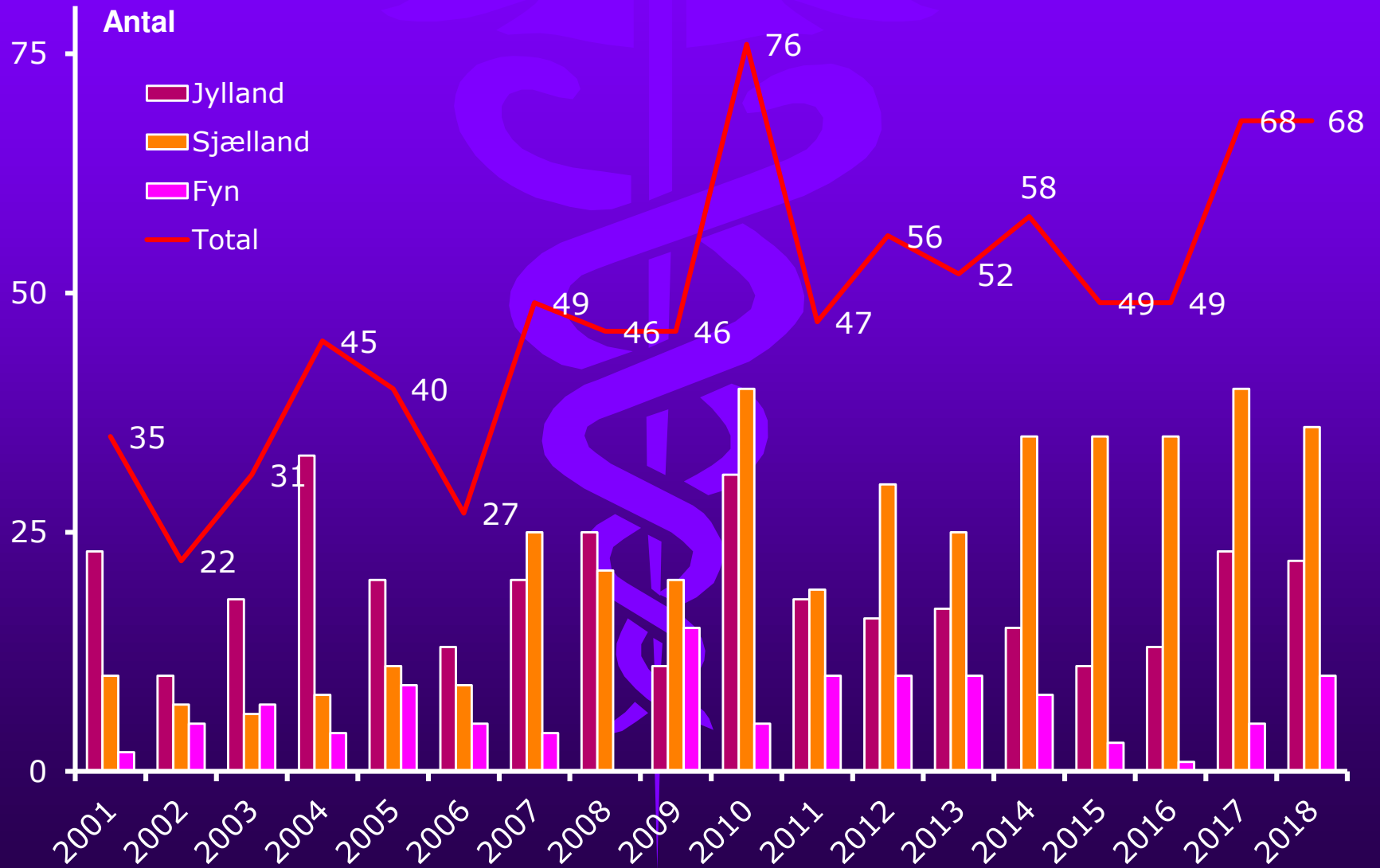
Uterusfibrom



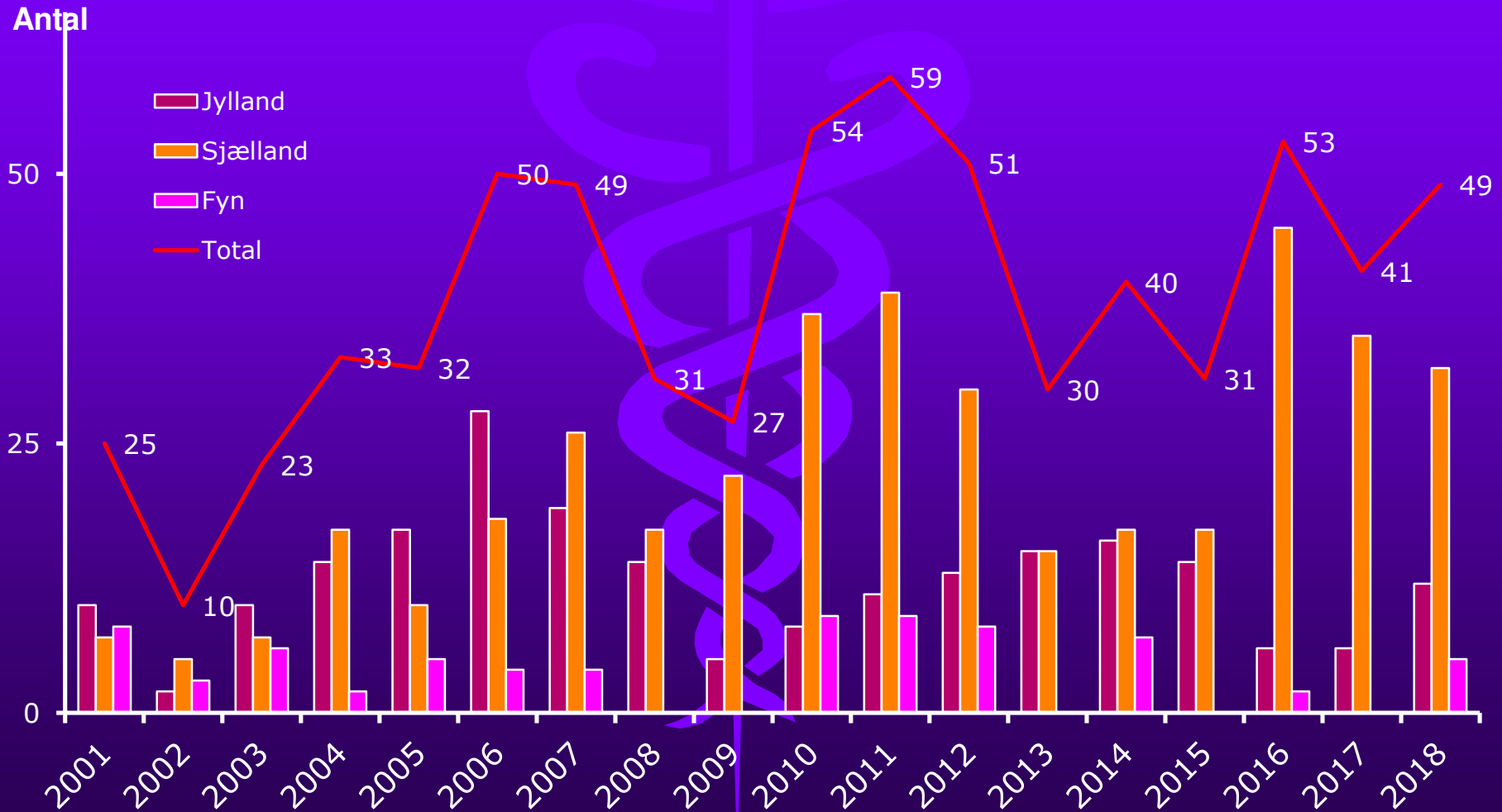
GI-Blødning



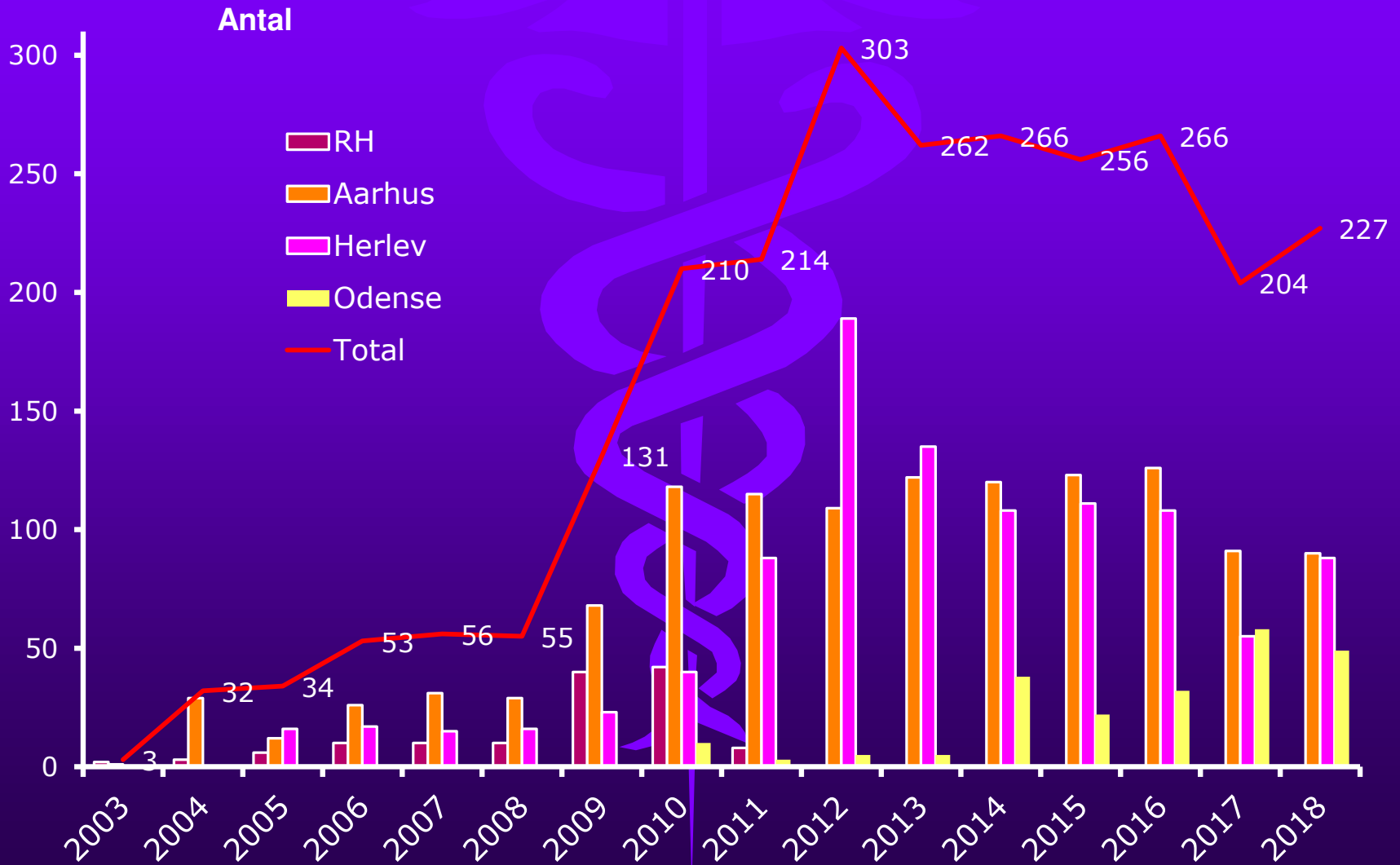
Traumer



Tumor Embolisering



Kemo-embolisering



DFIRs årsmøde 2020

