

Casepræsentation

Dennis Zetner

H-læge, Nordsjællands Hospital

76-årig mand

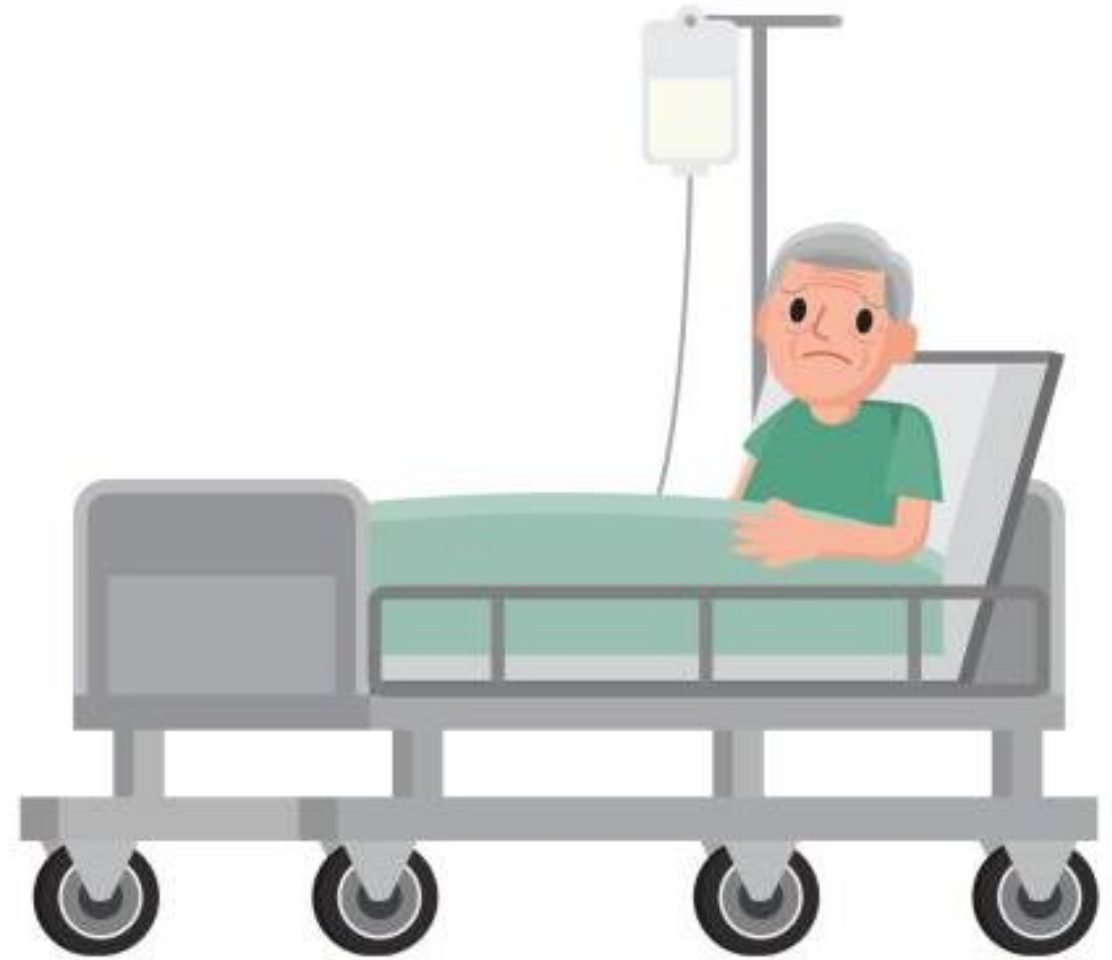- **Multimorbid**
 - KOL
 - Pacemaker
 - Arteriosklerose
- **Nyopereret (11 dage)**
 - Stentning af iliacakarrene





76-årig mand

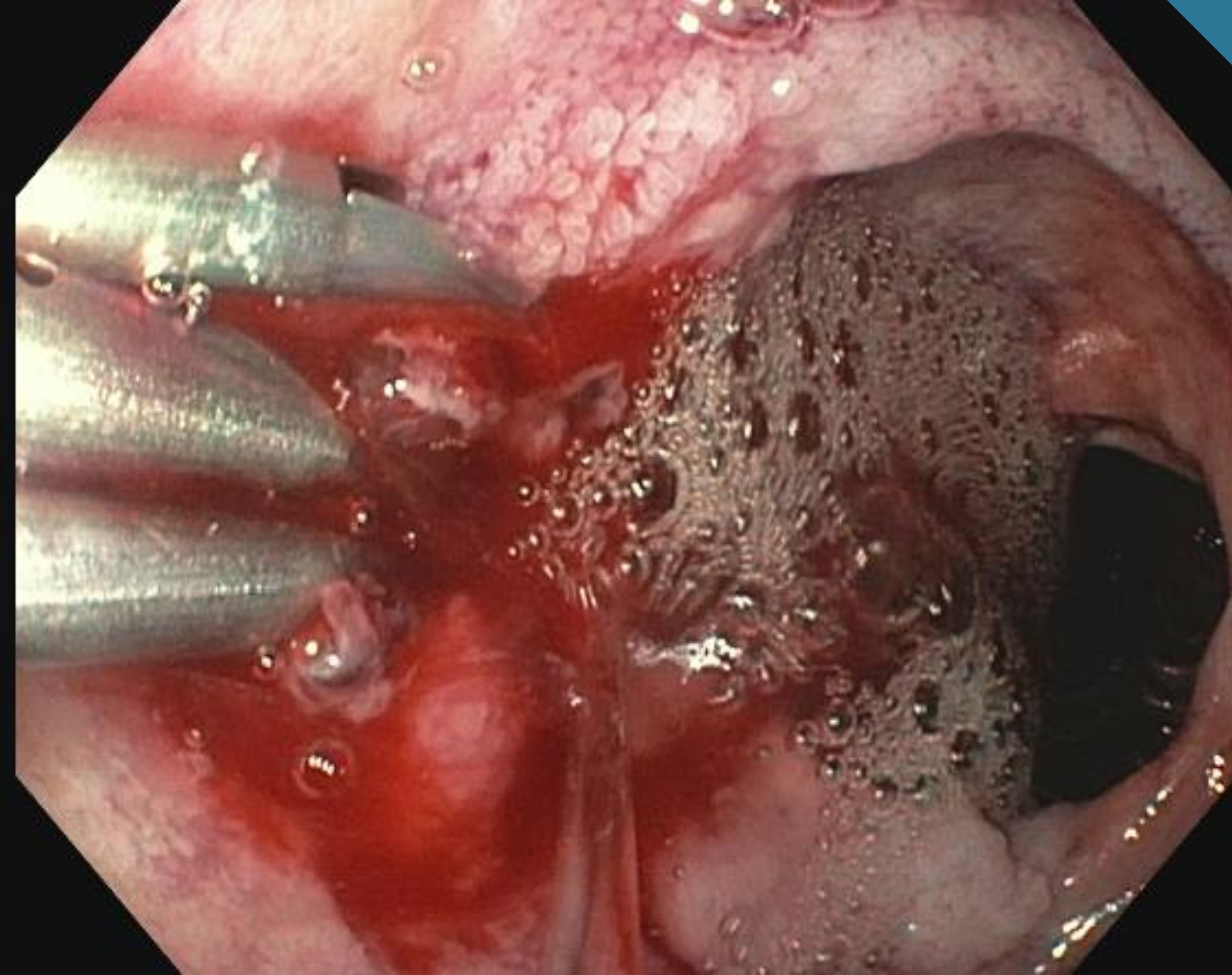
- Hæmatom i lyske
- Svimmelhed
 - BT 118/67
 - P 113
 - Hgb 4,0





1. Gastroskopi

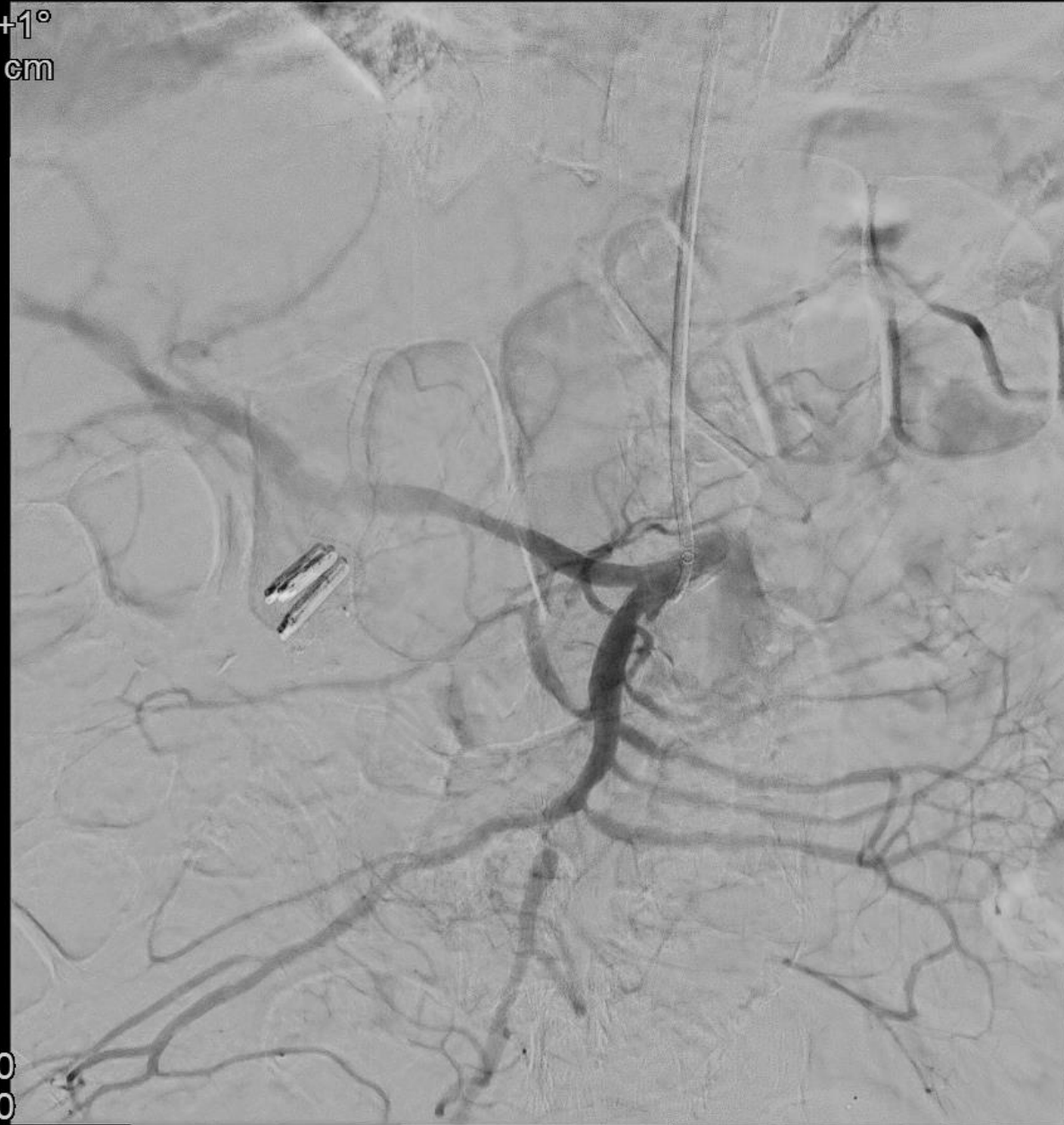
- Forrest 1b duodenalulcus
- Behandling
 - Adrenalinsaltvand
 - Hæmoclips
 - Kontaktkoagulation
- Hæmostase



1. Embolisering



Rot +1°
Ang +1°
FD 42 cm

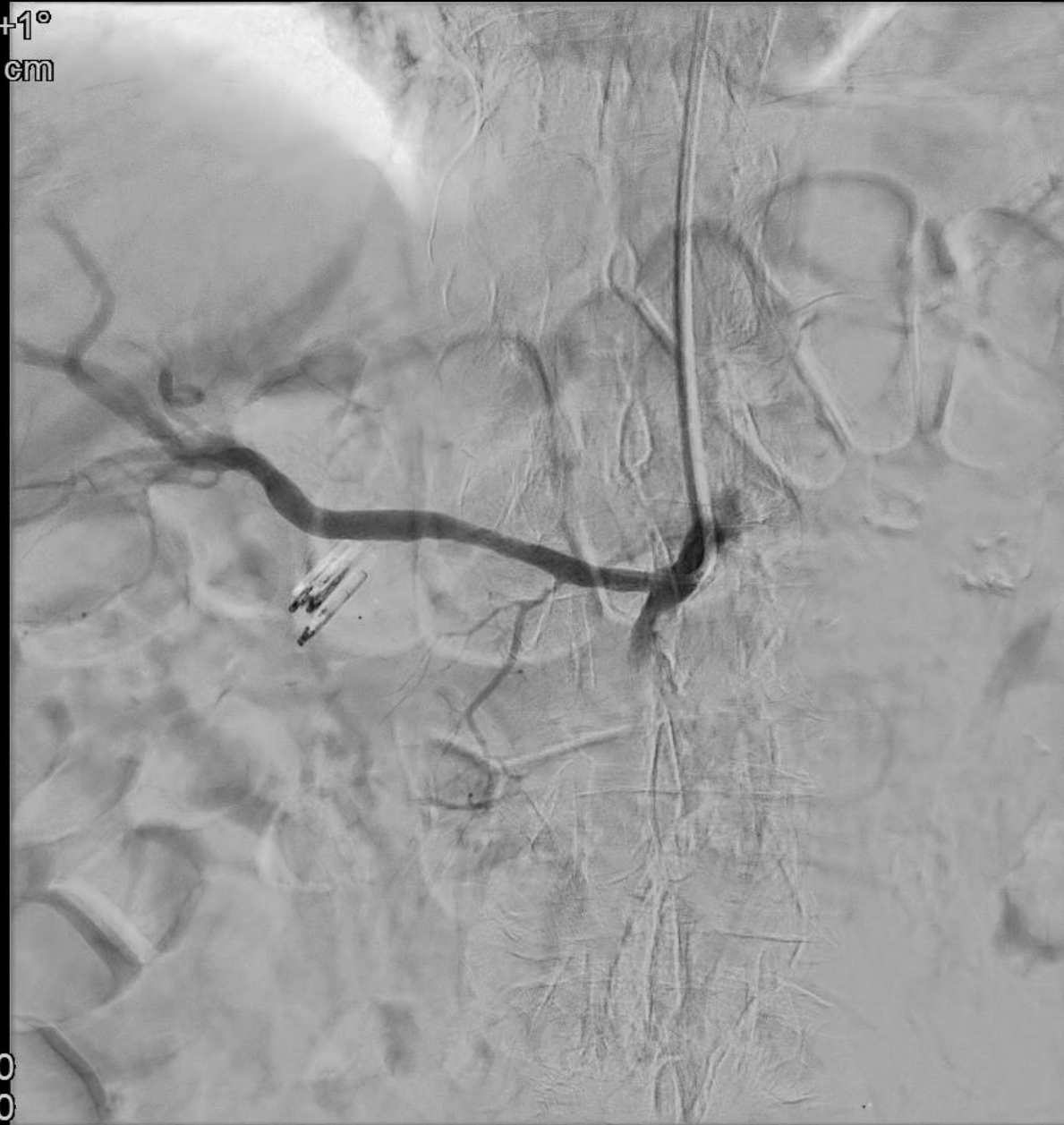


📄 1:50
📄 4:00
▶▶ 19:20:38

8
4-9



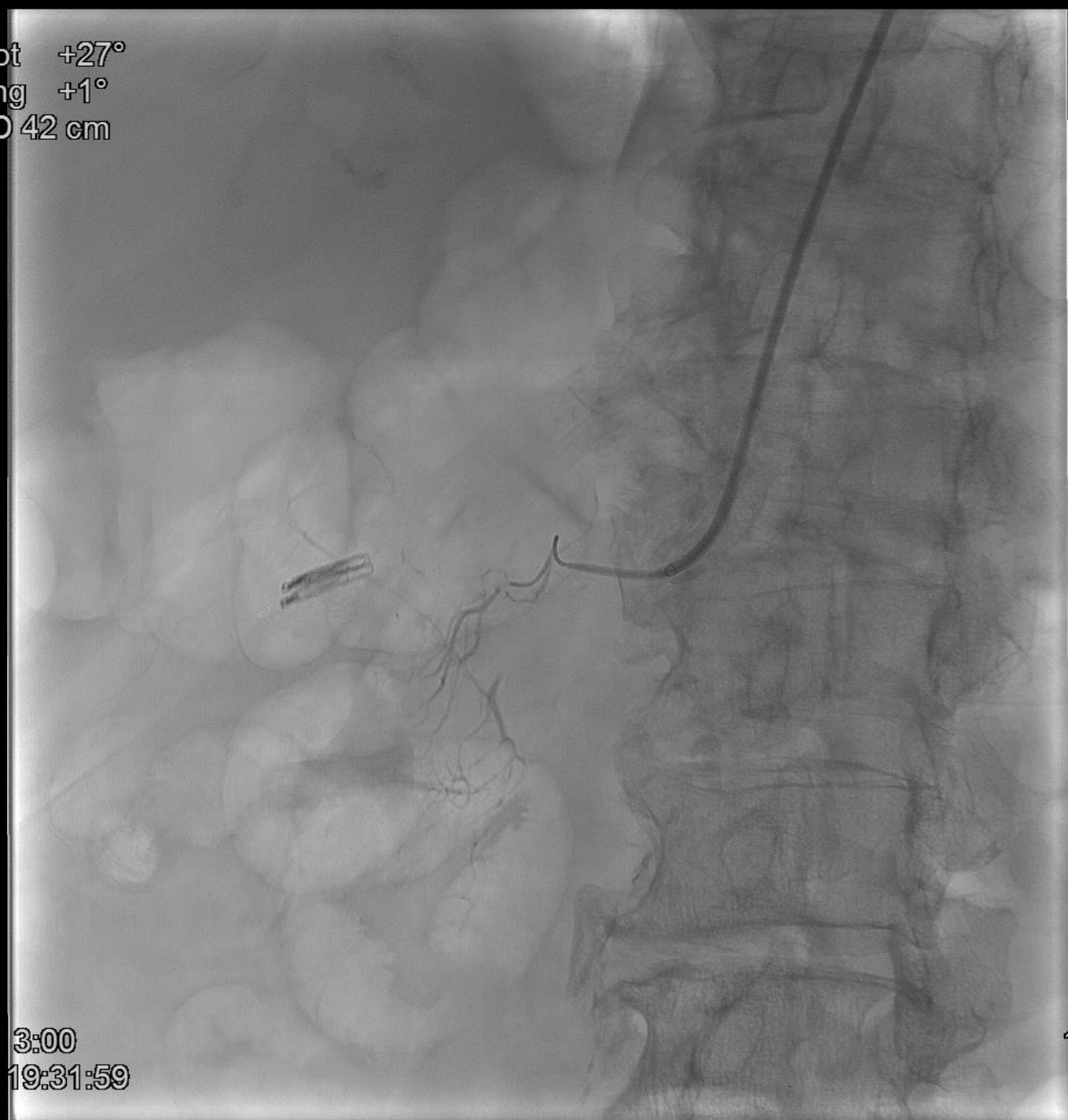
Rot +1°
Ang +1°
FD 42 cm



0:00
2:50
19:25:54

9
14-6

Rot +27°
Ang +1°
FD 42 cm



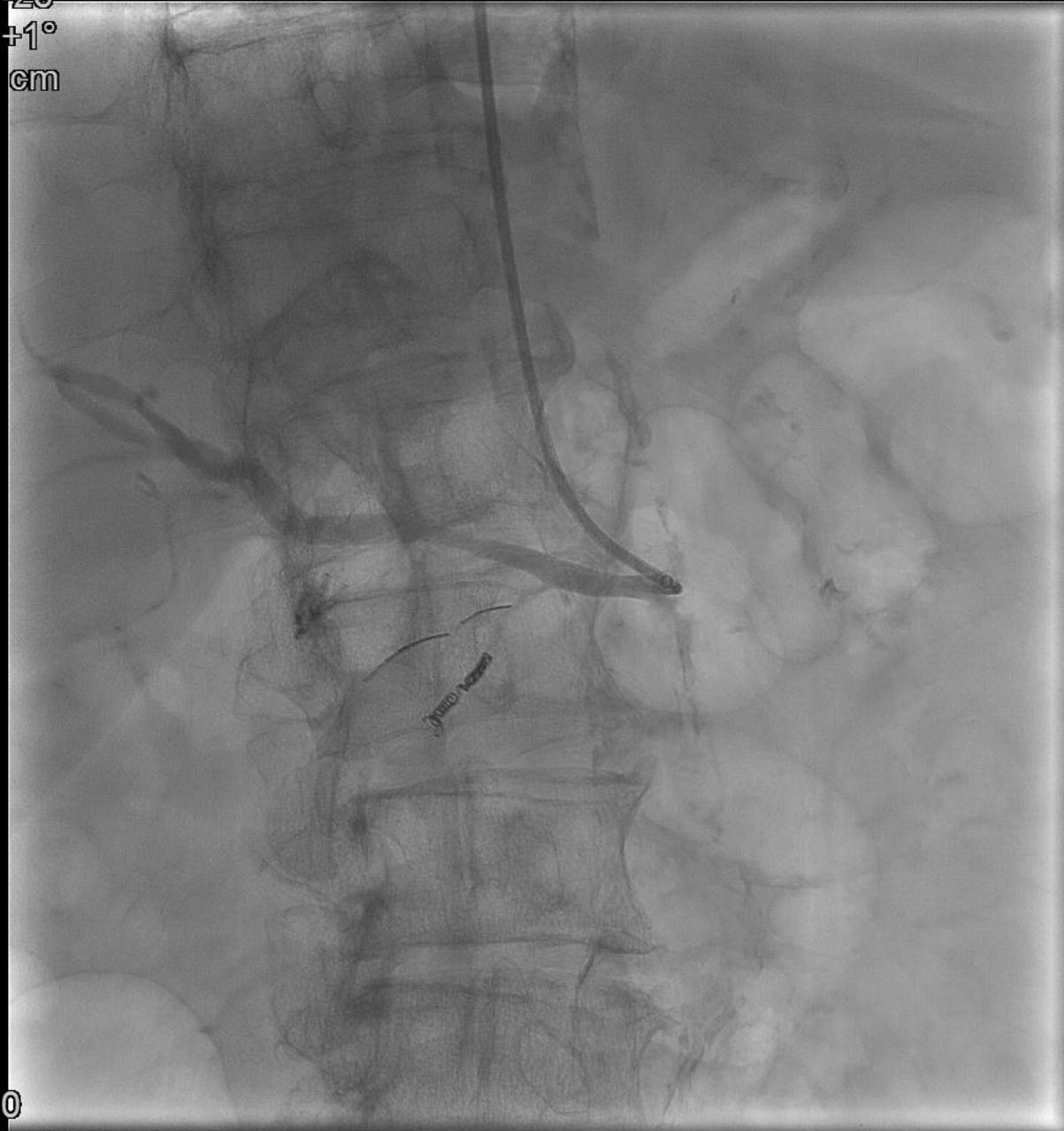
□ 3:00
» 19:31:59

11
7





Rot -26°
Ang +1°
FD 42 cm

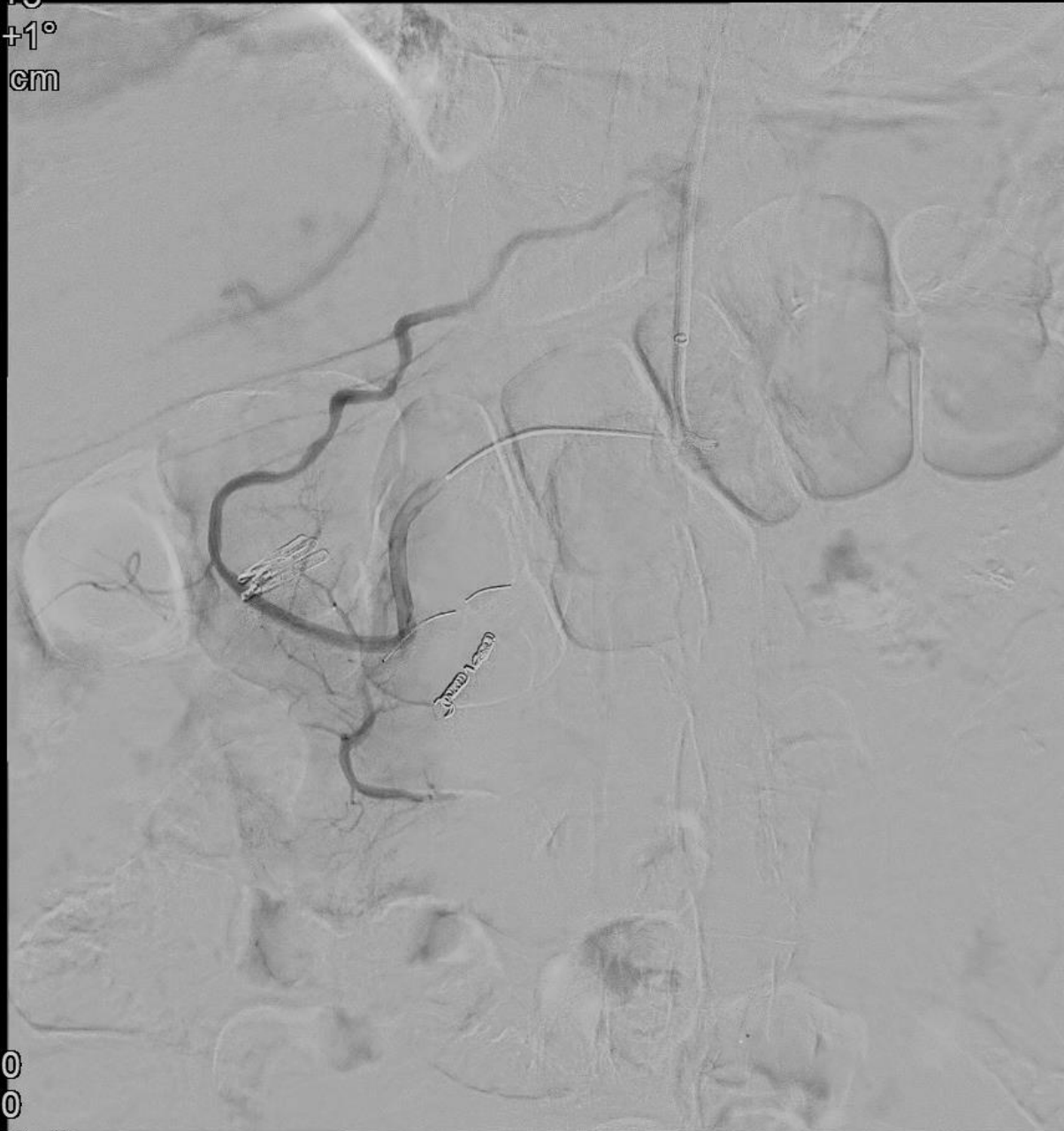


□ 2:50
» 19:40:08

20
6



Rot +3°
Ang +1°
FD 42 cm

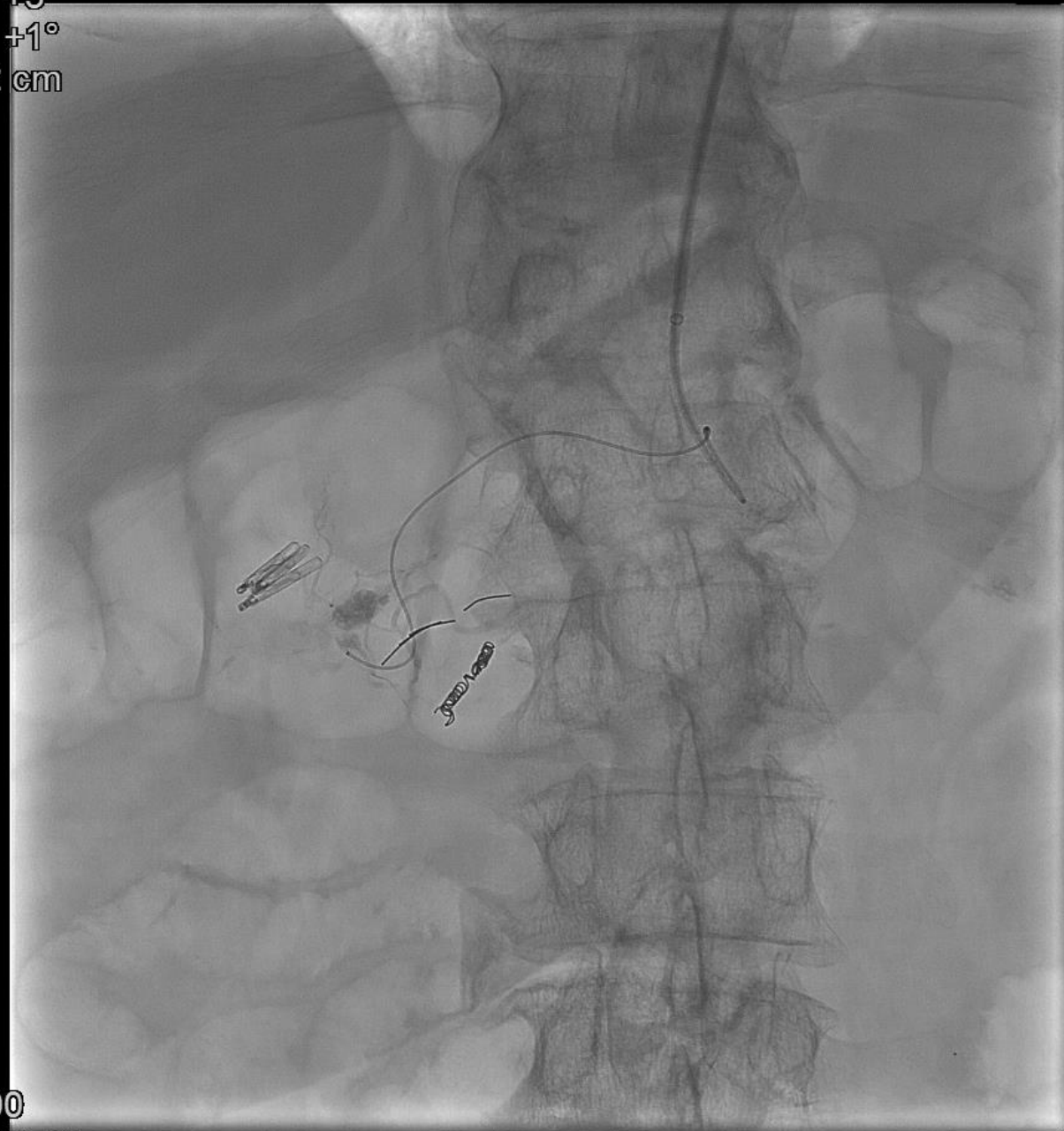


2:00
4:00
19:48:45

24
5-9



Rot +3°
Ang +1°
FD 42 cm

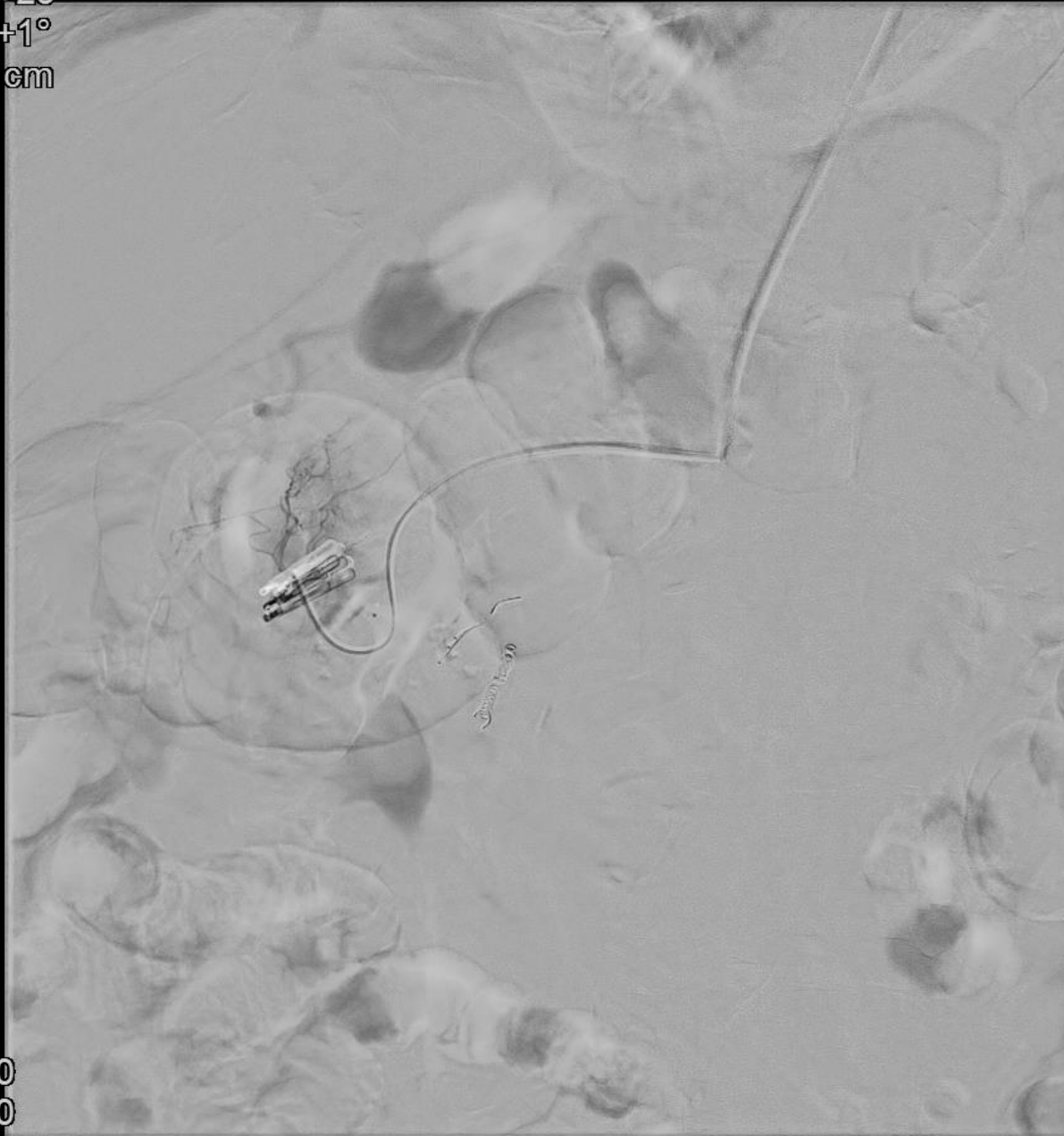


□ 4:00
» 19:59:56

27
9



Rot +29°
Ang +1°
FD 42 cm

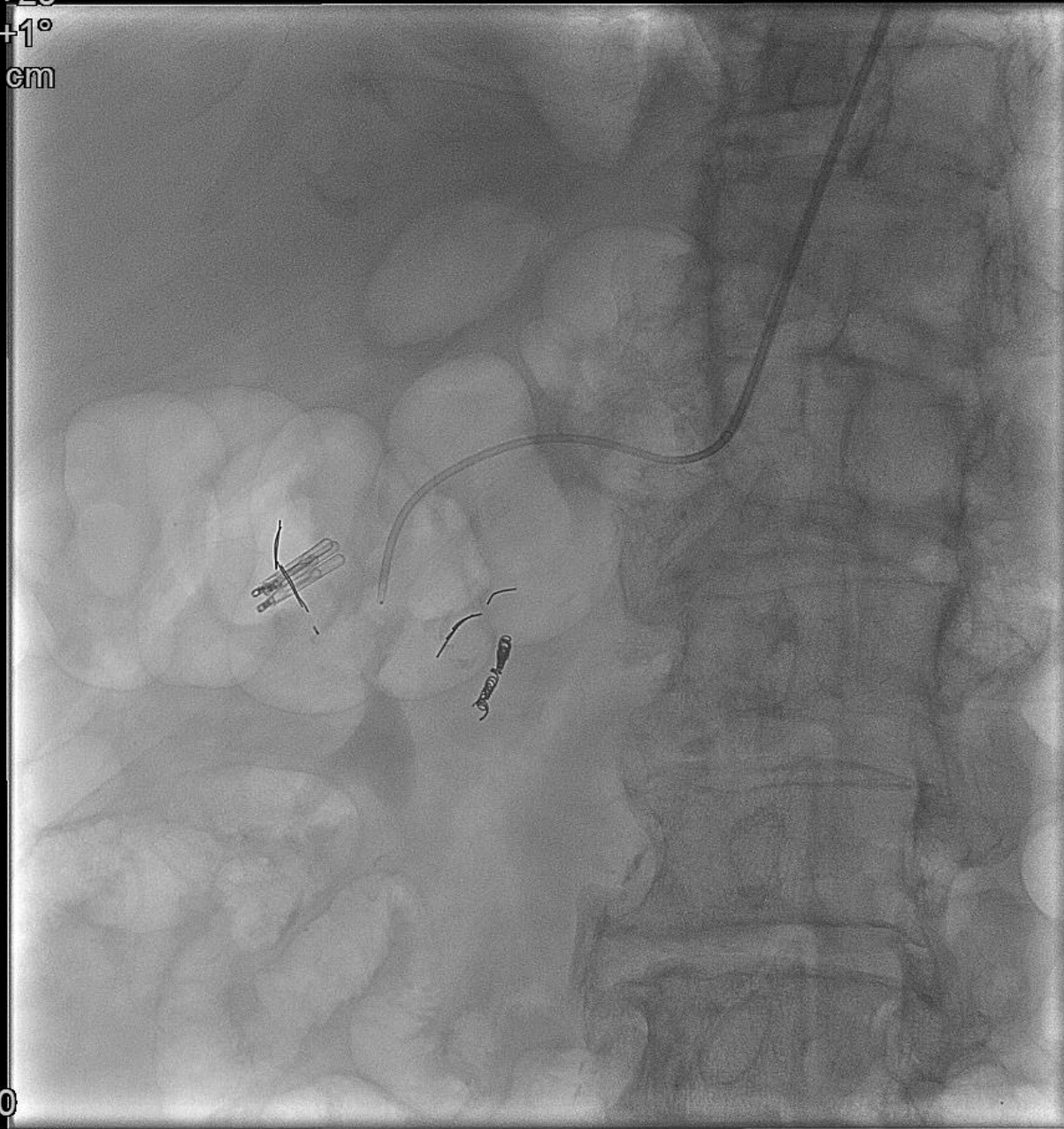


0:00
4:00
20:13:01

35
11-9



Rot +29°
Ang +1°
FD 42 cm

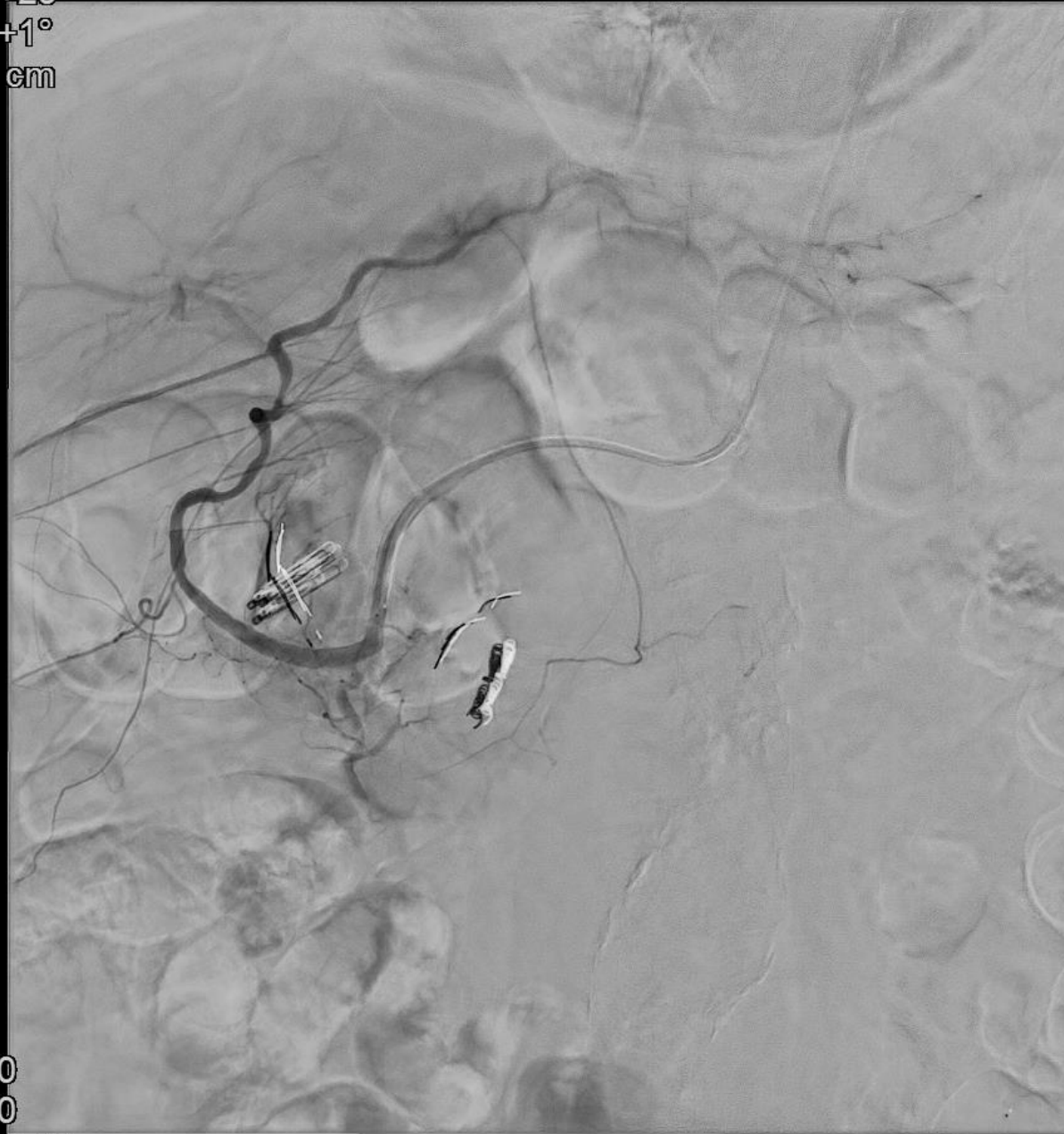


□ 0:50
» 20:25:22

39
2



Rot +29°
Ang +1°
FD 42 cm



0:00
4:50
20:25:22

39
15-10



5 dage postoperativt

- Melæna
- Hgb 5,4 → 4,0





2. Gastroskopi

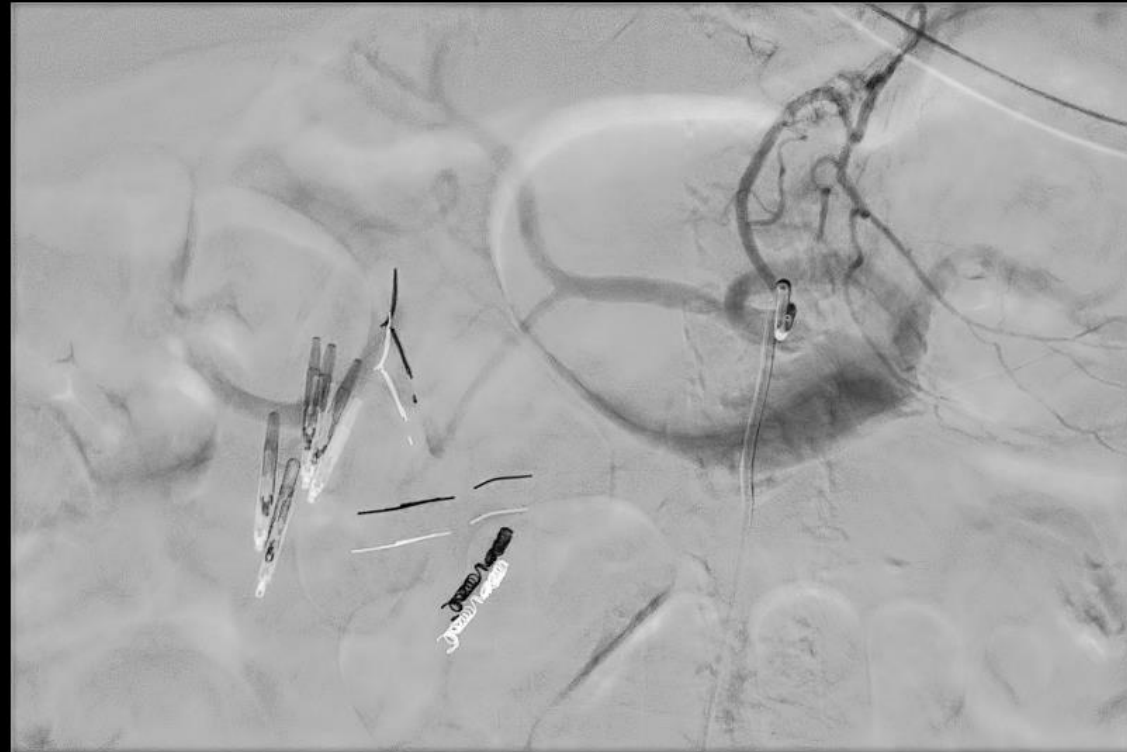
- Sivblødning nær clips
- Behandling
 - Adrenalinsaltvand
 - To yderligere clips
- Hæmostase



2. Embolising



Rot -3°
Ang -1°
FD 42 cm

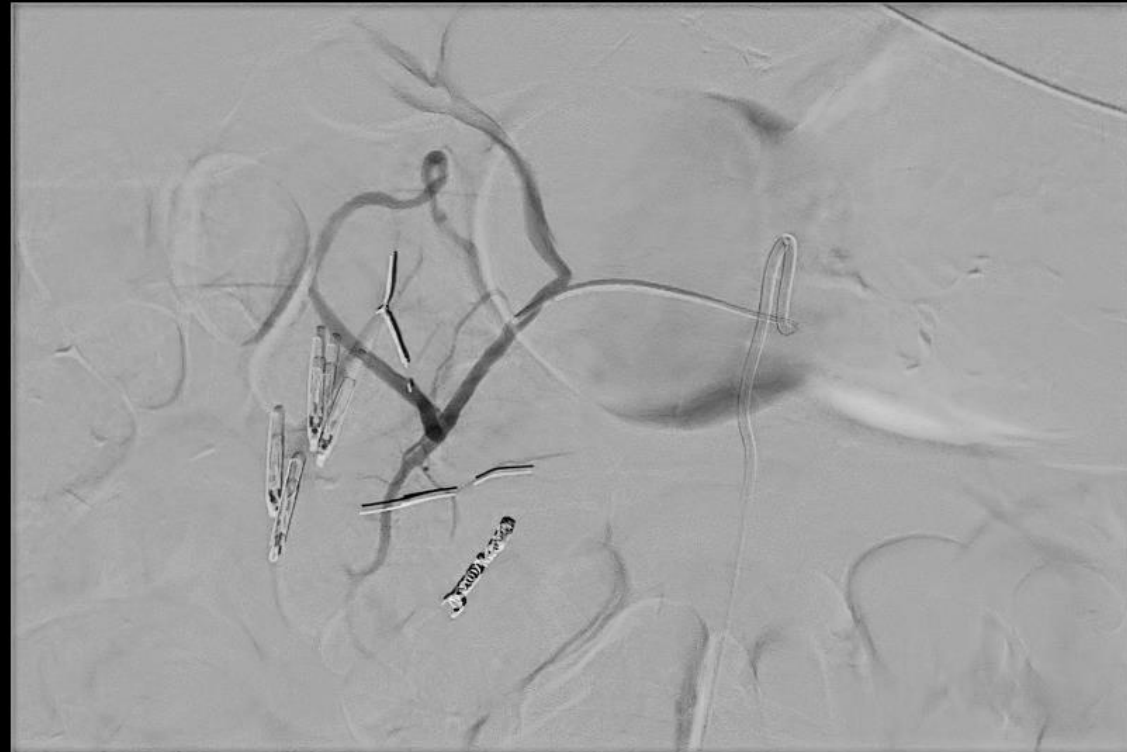

📄 0:00
🕒 3:00
⏮ 17:38:24

10
14-7



Rot -3°
Ang -1°
FD 42 cm

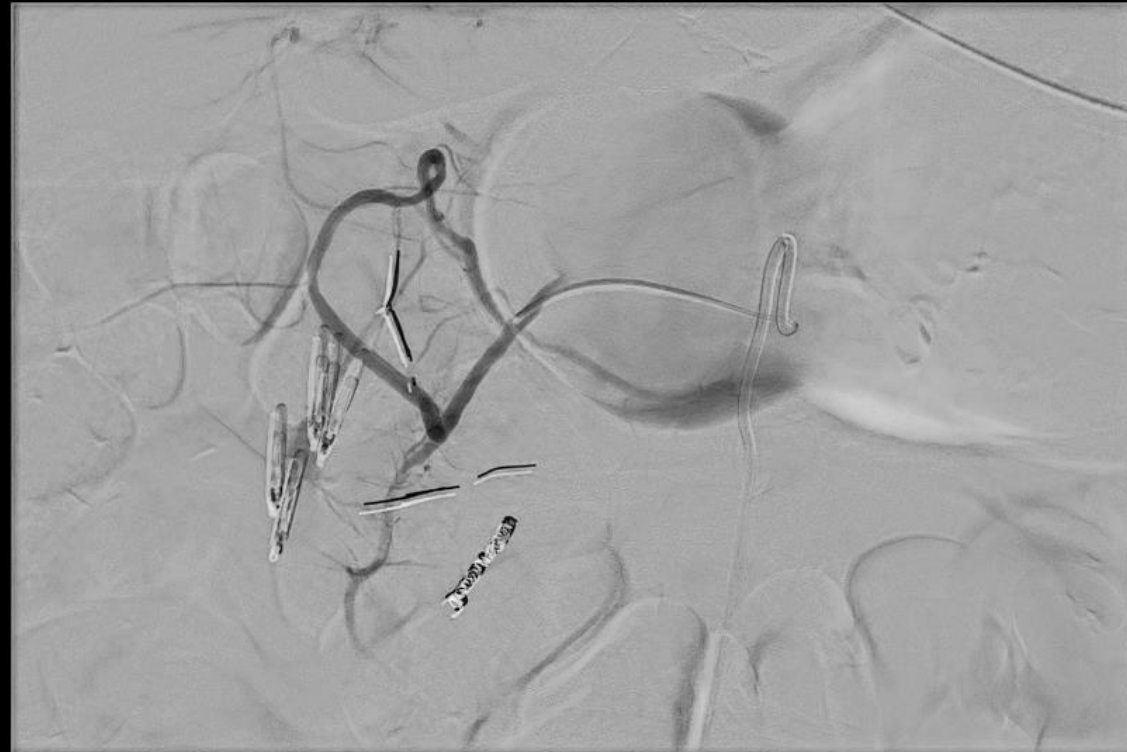

0:00
2:50
17:41:06

11
19-6



Rot -3°
Ang -1°
FD 42 cm

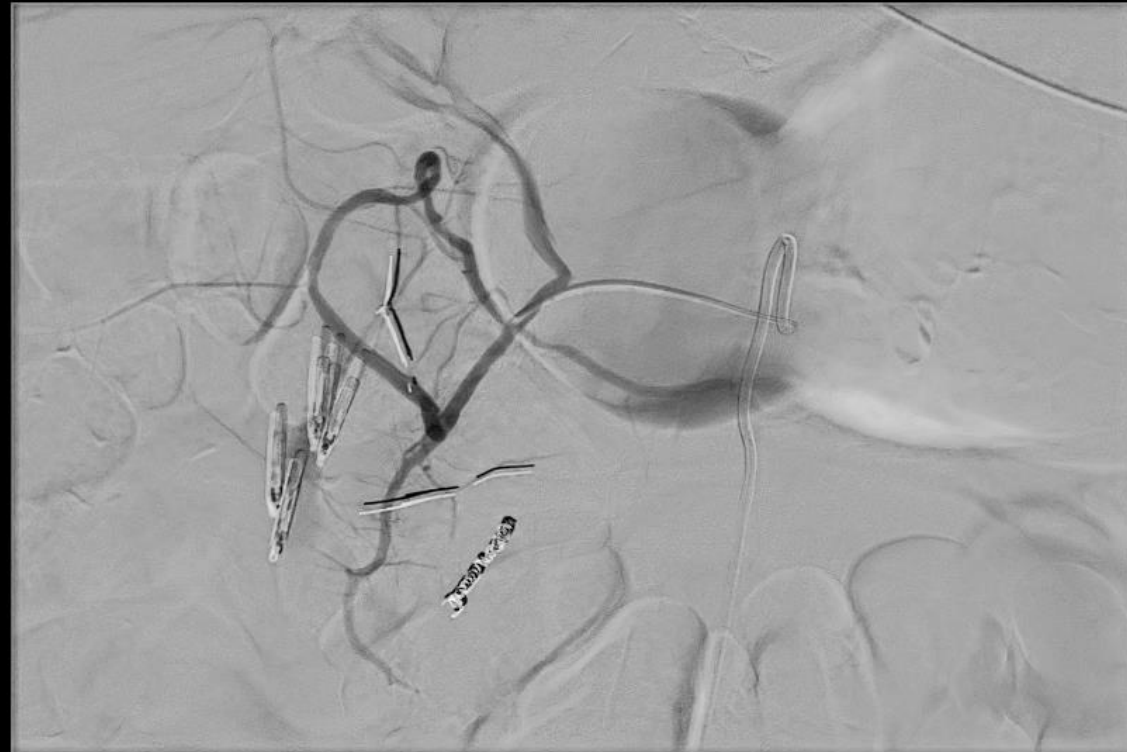

📄 0:00
🕒 3:00
⏮ 17:41:06

11
19-7



Rot -3°
Ang -1°
FD 42 cm

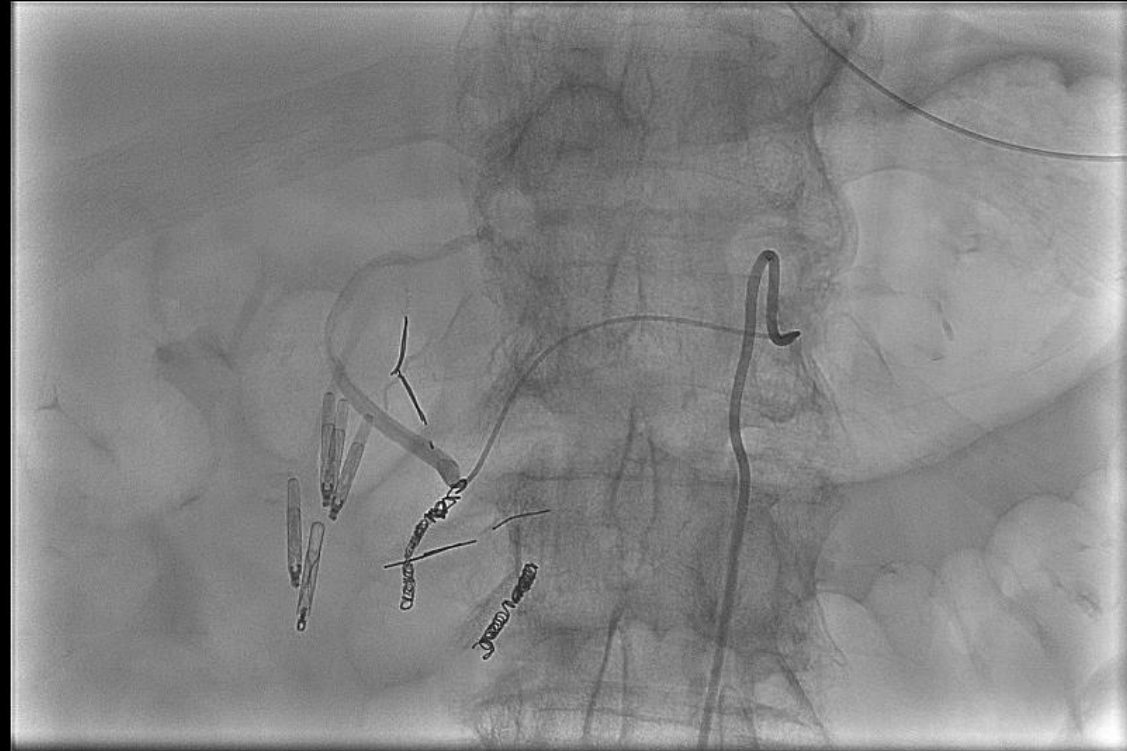


📄 0:00
🕒 3:50
⏮ 17:41:06

11
19-8



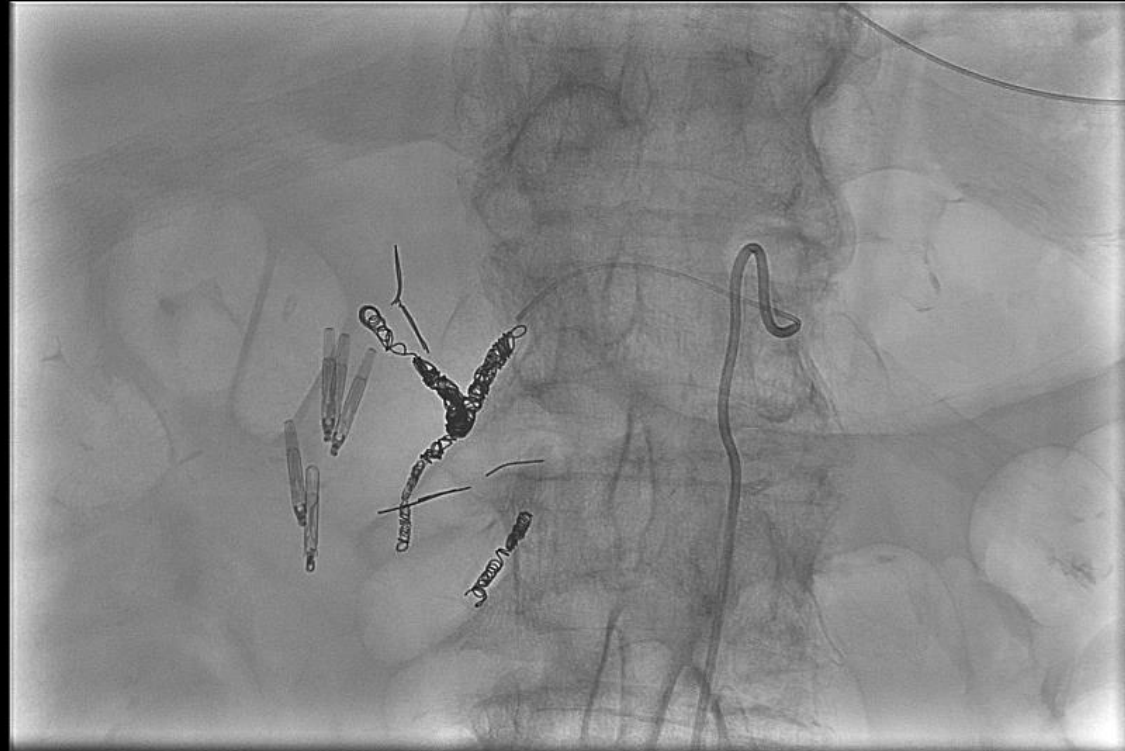
Rot -4°
Ang -1°
FD 42 cm



□ 1:50
» 18:04:16

17
4

Rot -4°
Ang -1°
FD 42 cm

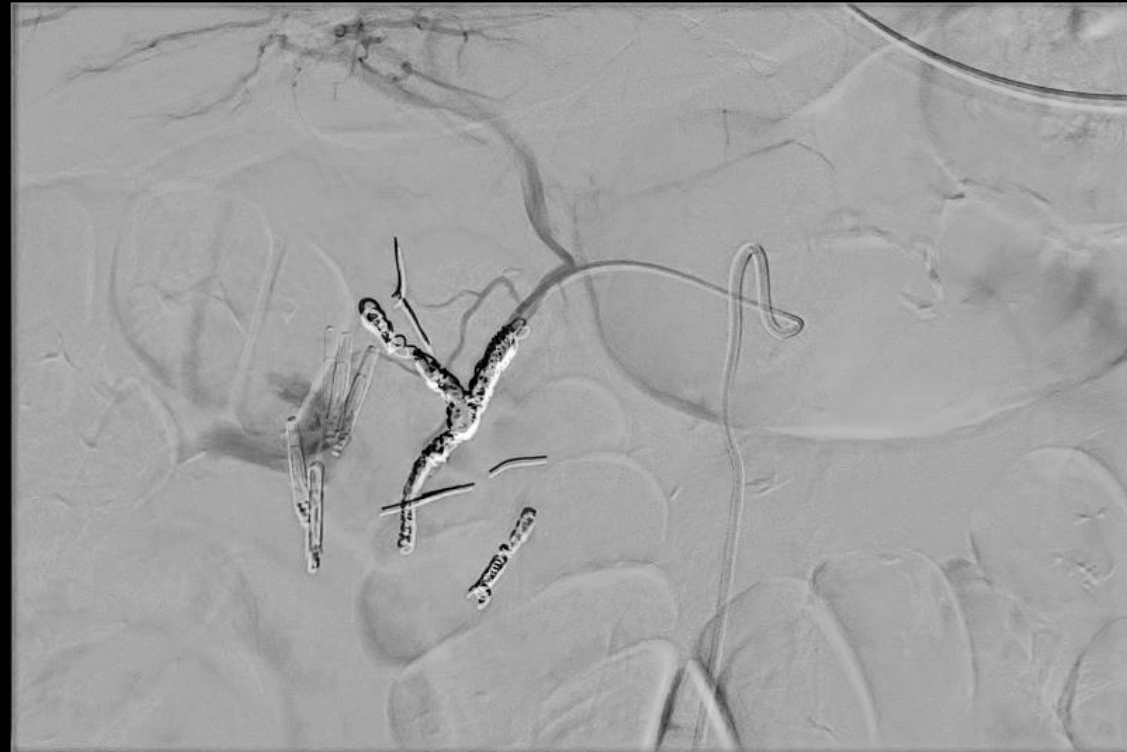

□ 1:50
» 18:15:32

18
4



Rot -4°
Ang -1°
FD 42 cm

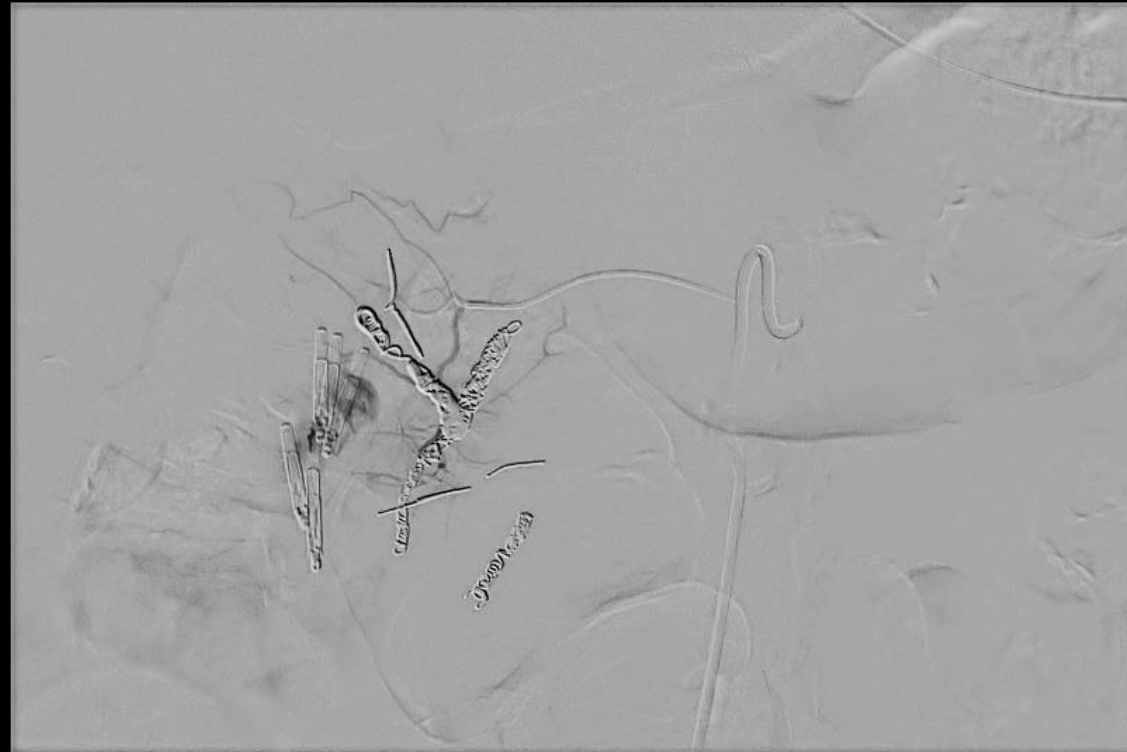

📄 0:00
🕒 3:50
⏮ 18:15:32

18
20-8



Rot -4°
Ang -1°
FD 42 cm

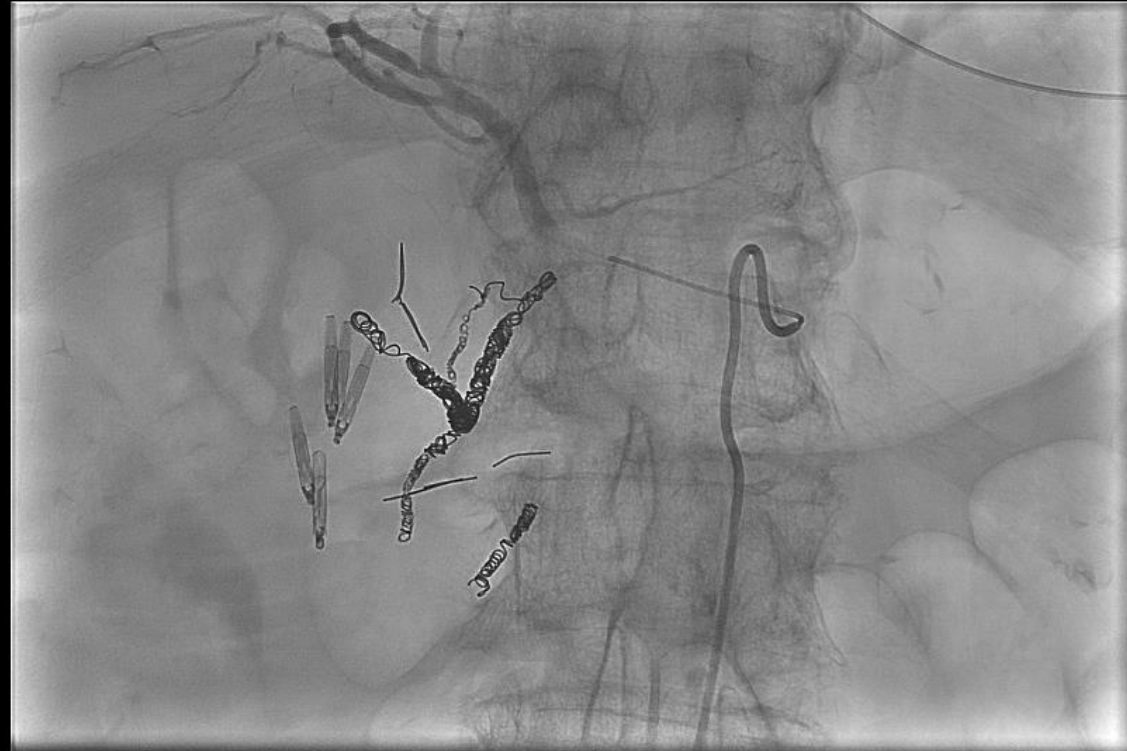


📄 0:00
🕒 2:00
⏮ 18:18:18

19
13-5



Rot -4°
Ang -1°
FD 42 cm

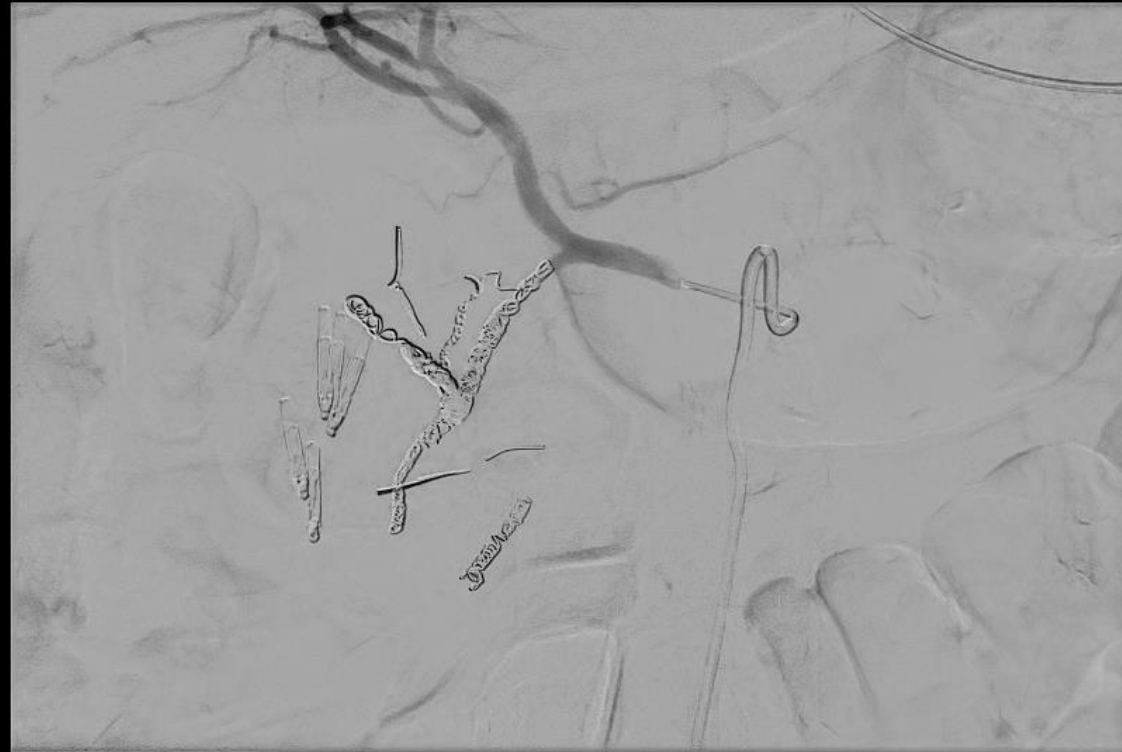


□ 4:00
» 18:27:08

22
9



Rot -4°
Ang -1°
FD 42 cm



0:00
3:00
18:27:44

23
13-4..7

Postoperativt

- Melæna hver 4.-5. dag
 - Gastroskopi x 3
 - Koloskopi x 2
 - Kapselendoskopi x2
- Ingen blødningskilde fundet



Postoperativt

- Langt efterforløb
 - COVID-19
 - Cerebralt infarkt
- Udskrives efter 3 måneder



Overvejelser

- Targetteret behandling?
- Skal GDA altid coiles?
- Hvor blødte patienten?





Spørgsmål?