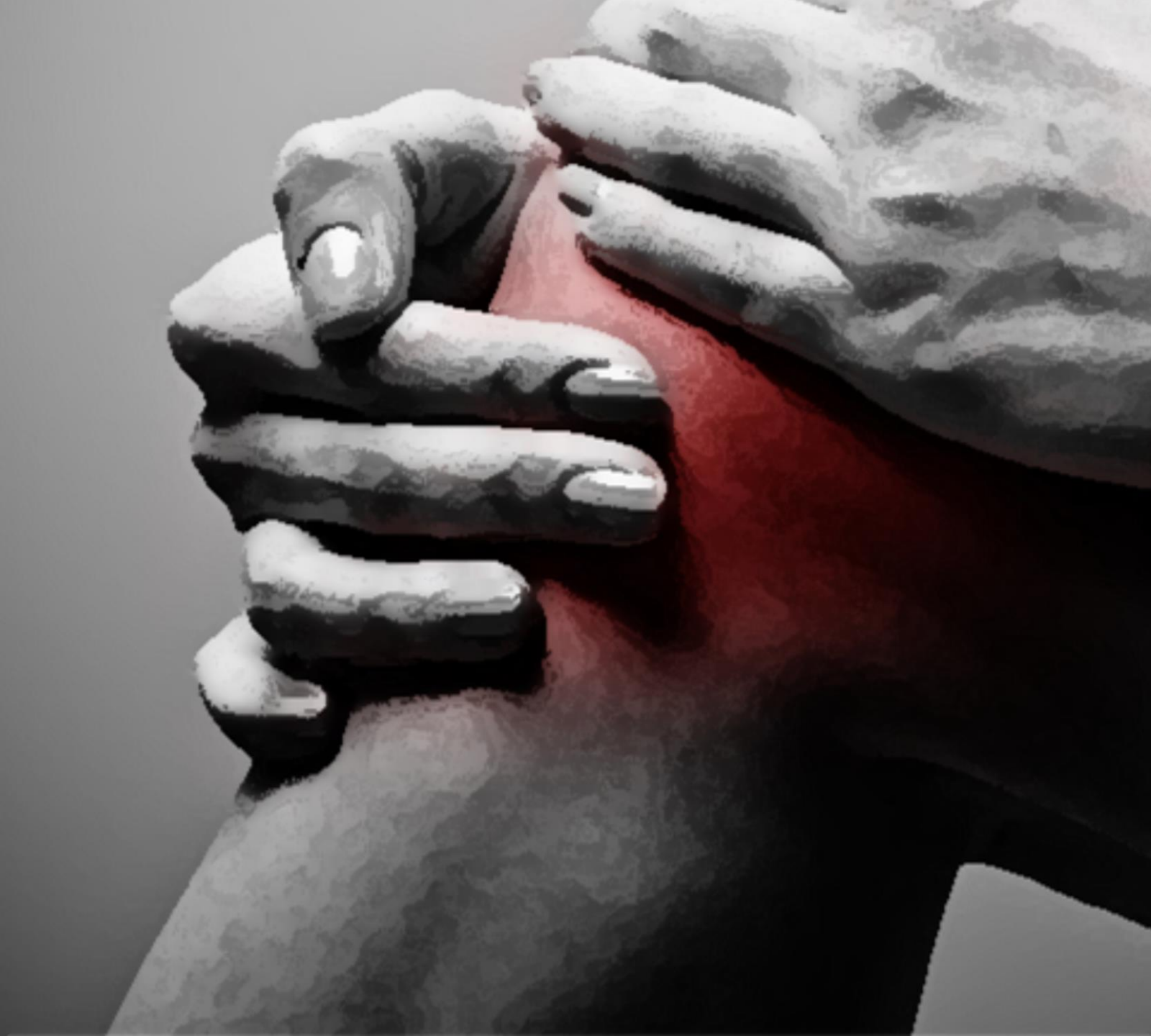



# CASE

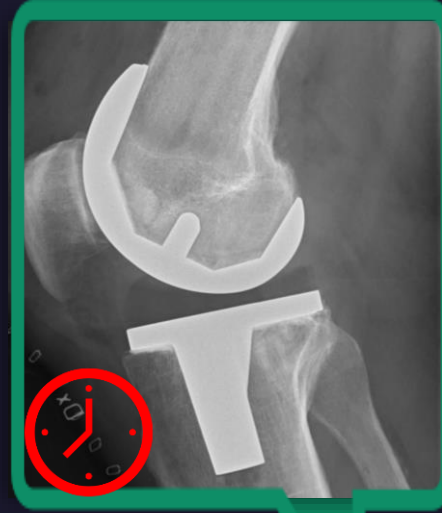## Knæ-embolisering

Louise Hindsø

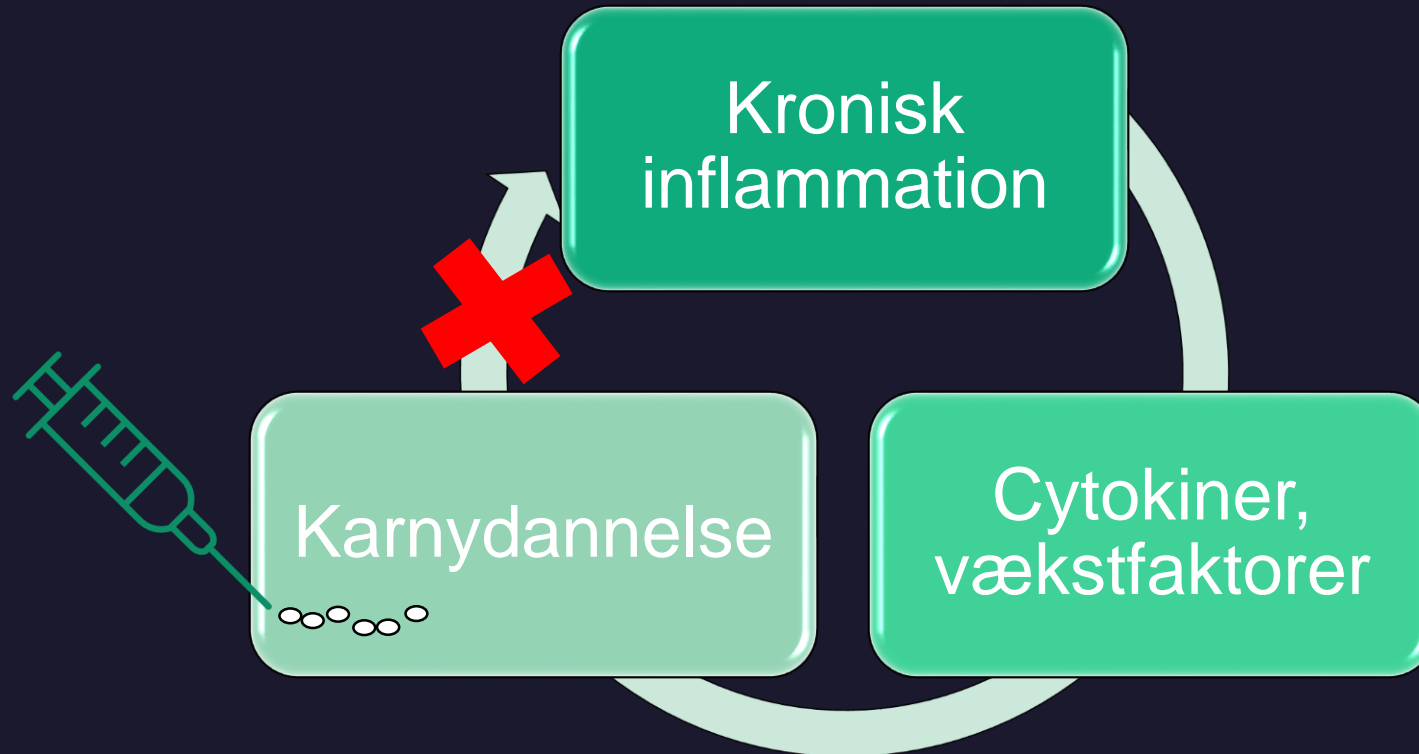
Læge, Phd-studerende

Afdeling for Røntgen og Skanning,  
Rigshospitalet

# Patienthistorie



# Behandlingsprincip



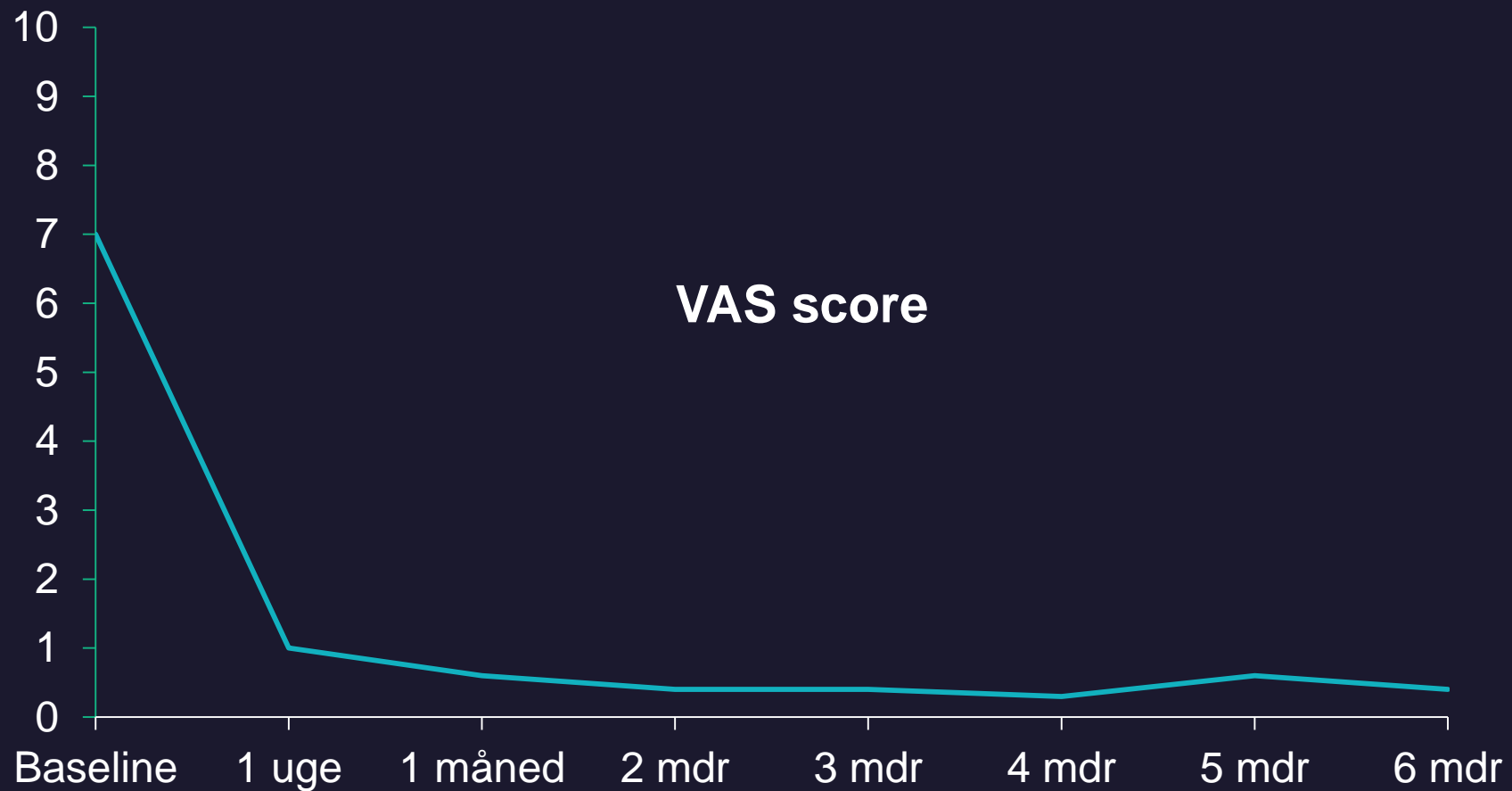
# Indgrebet

- Antegrad femoral adgang (90%)
- 4 Fr sheath - C2 kateter
- 1,7 Fr Mikrokateter
- Nitroglycerin
- Cone beam/Kølepose
- Fra 0,2 mL 100-300 $\mu$ m Embospheres

# Bivirkninger

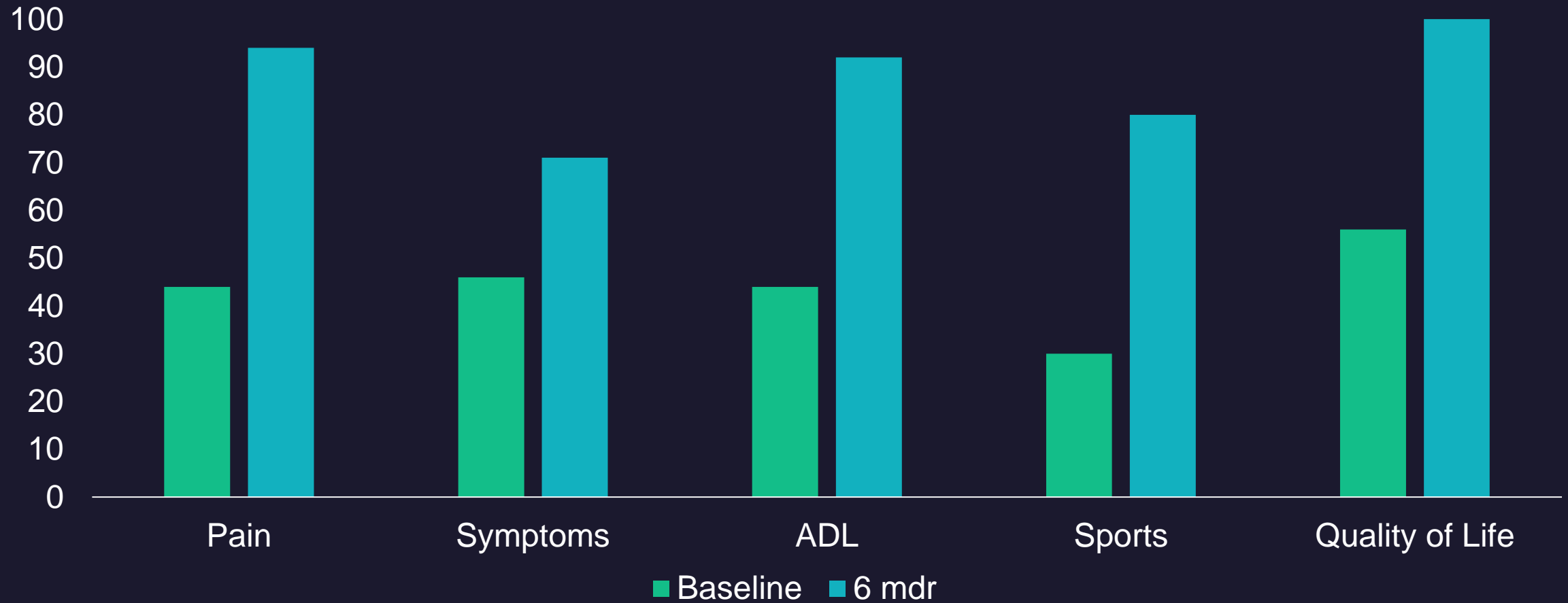
- Forværring af knæ smerter 2-4 dage post embolisering
- I øvrigt intet

# Behandlingsrespons

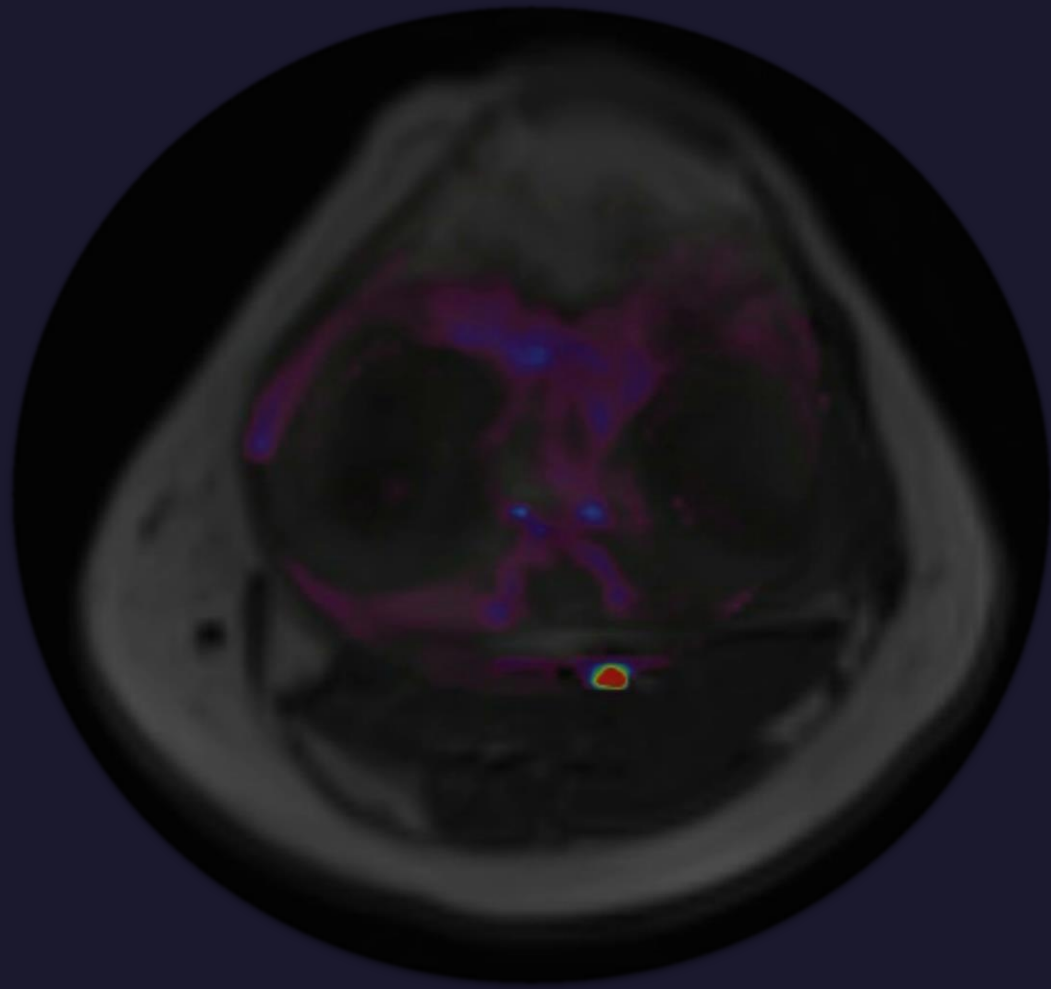
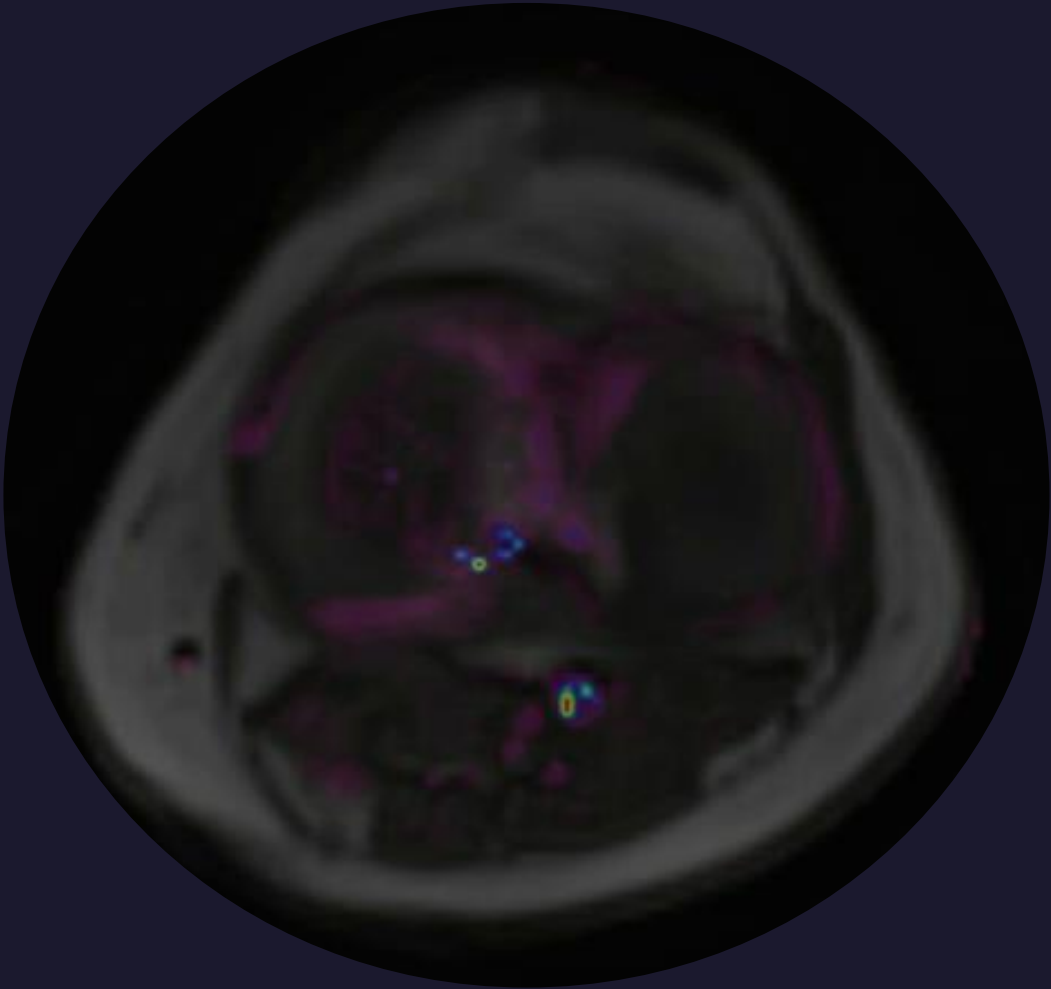


# Behandlingsrespons

KOOS Score



# Perfusions MRI







Tak for opmærksomheden

Louise Hindsø, [louise.hindsoe@regionh.dk](mailto:louise.hindsoe@regionh.dk)

# Behandlingsrespons

## Fysiske tests

