

# Case battle

Neurointerventions case.



RH 1/6-23 - Marie Kessel

# Traume:

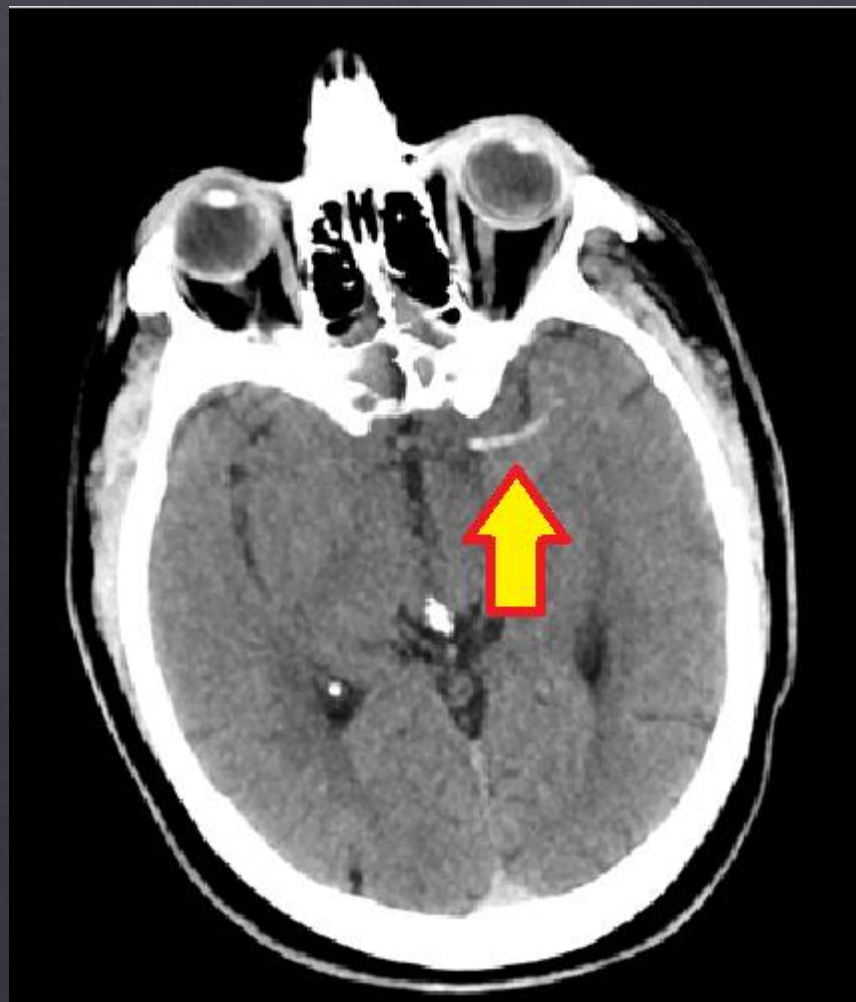

- ◇ 62 årig herre. Sammenstød med anden bil. Estimeret 90 km/t
- ◇ Kendt med hypertension, søvnapnø og mulig diabetes.
- ◇ Højresidig hemiparese, blikdeviation mod venstre og afasi
- ◇ FAST negativ. Scannes på egne konditioner.

Traumescanning: KL 12.30

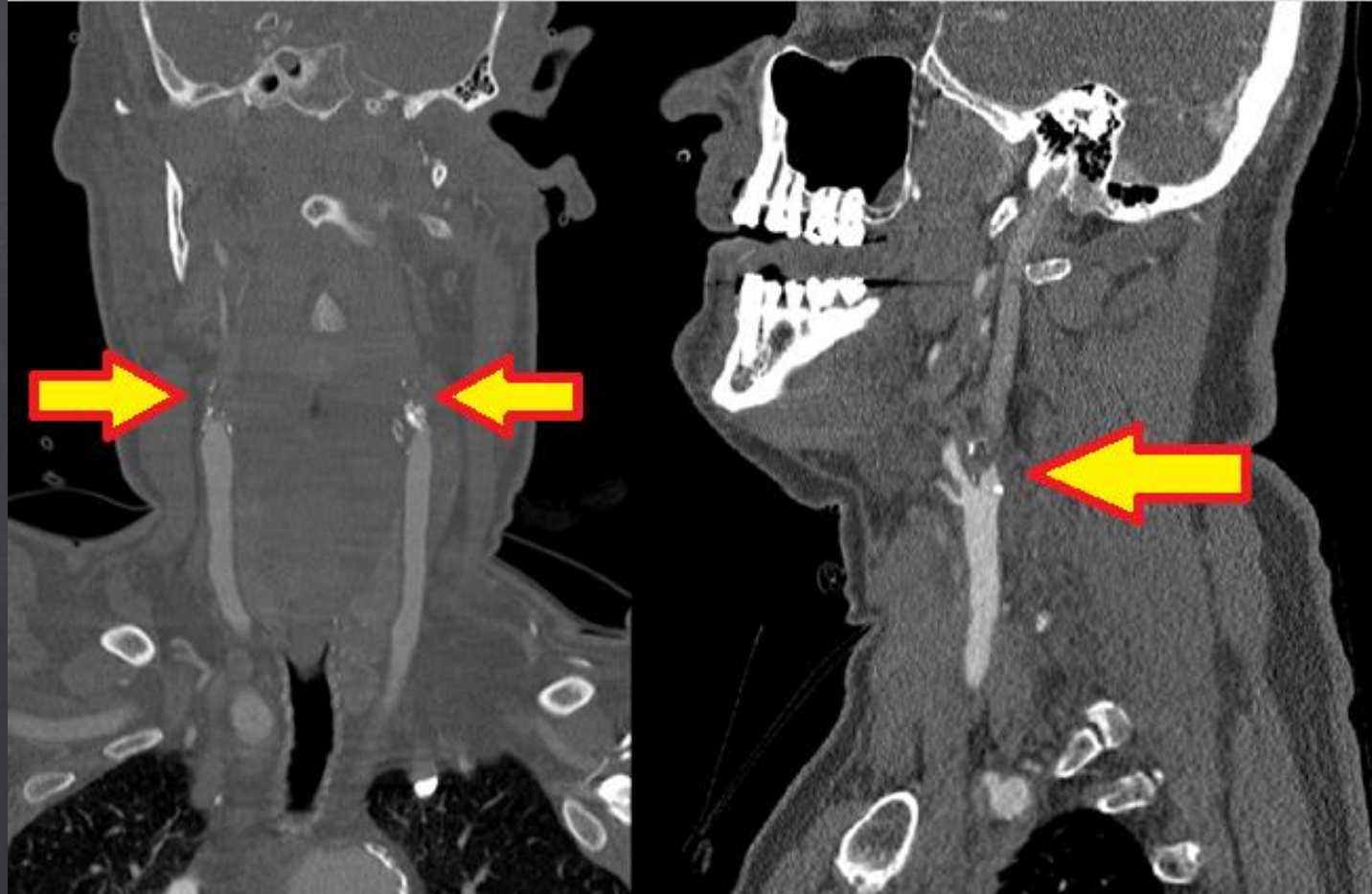


# Dense artery sign





# Cerebral angiografi



Time is brain



1 million neuroner per minut.

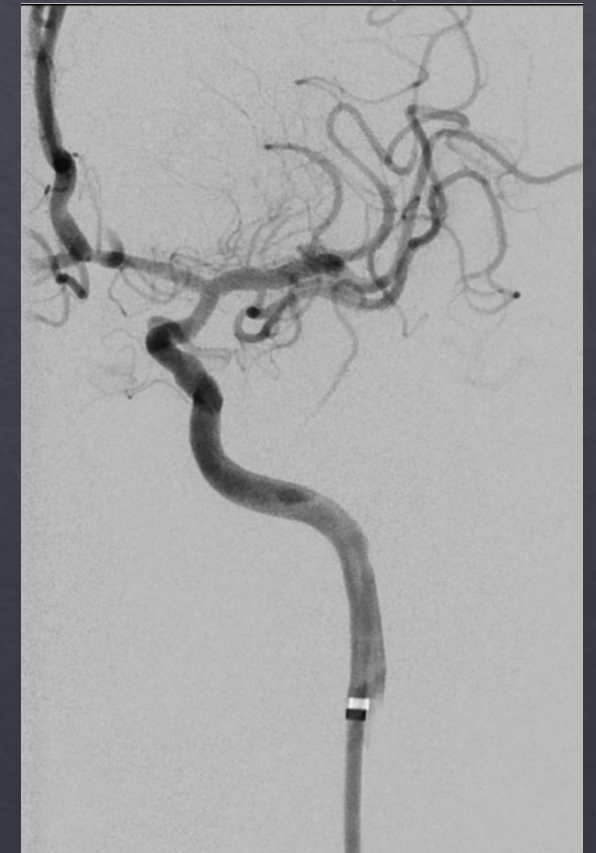
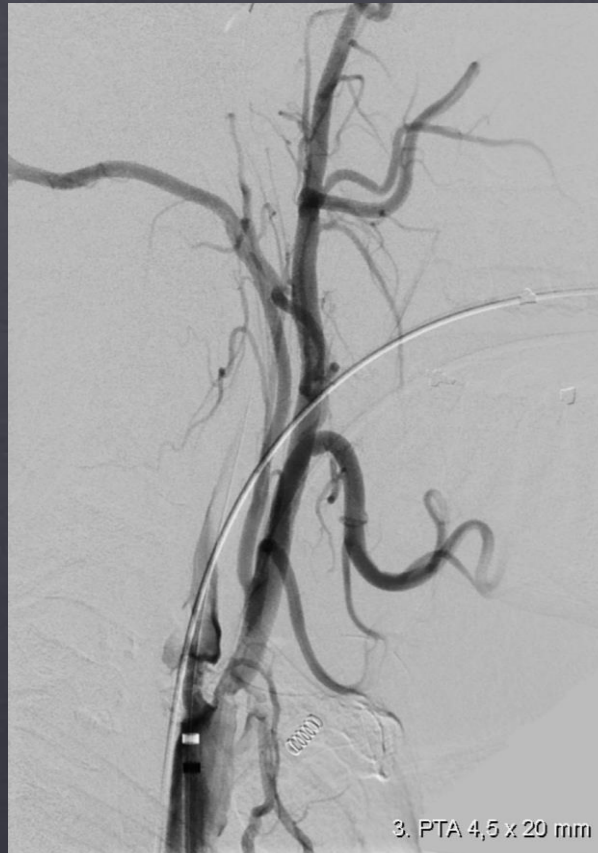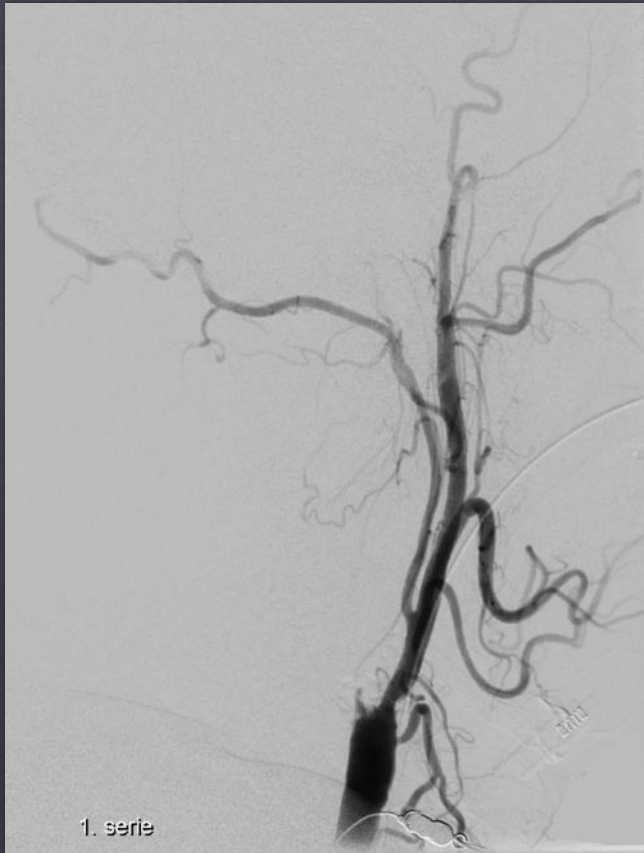
# Pt køres til trombektomi: Punktur 13.12



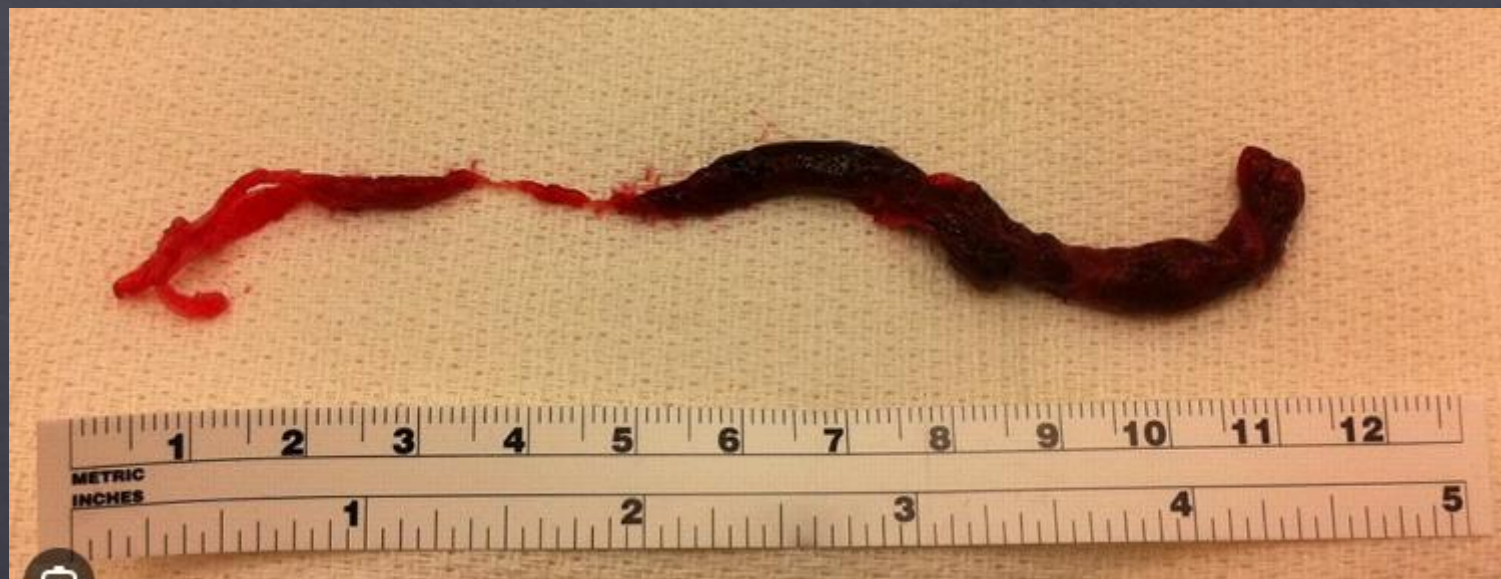13.16

14.14

14.19





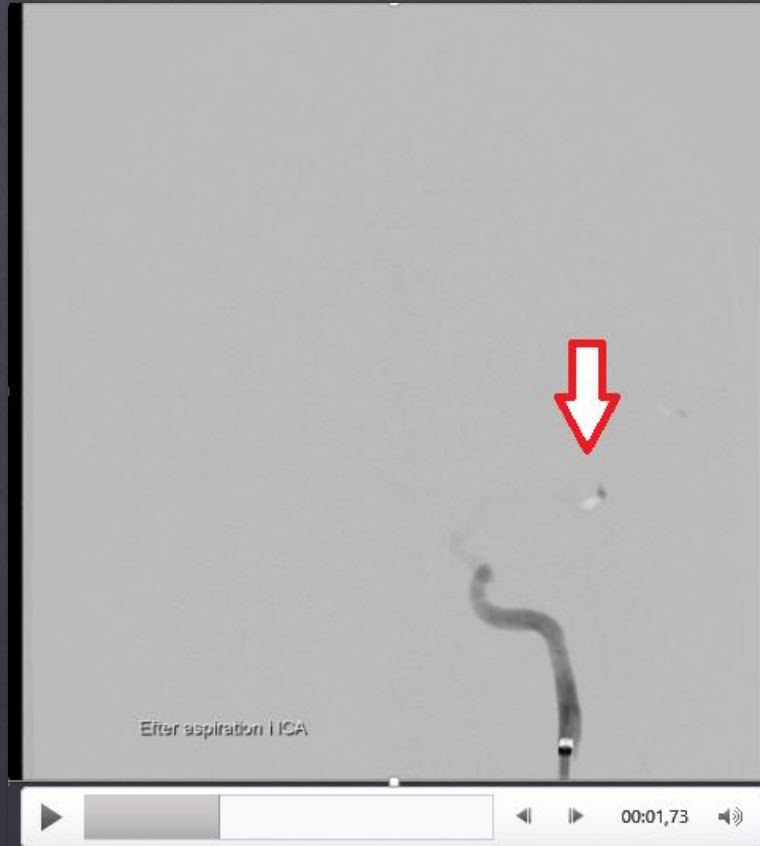




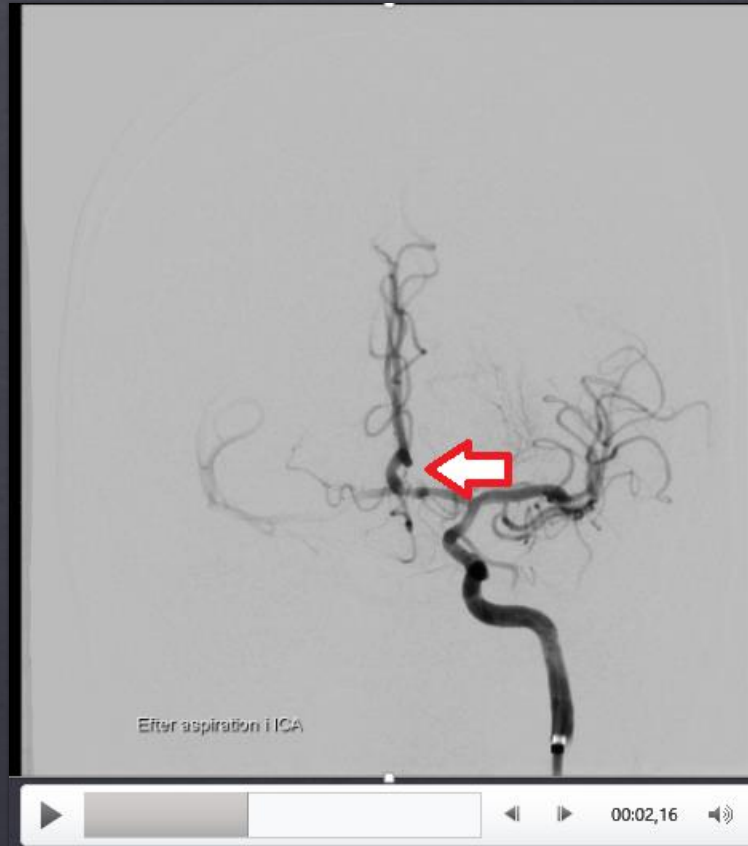
# Efter aspiration i ACI



# After aspiration i ACI

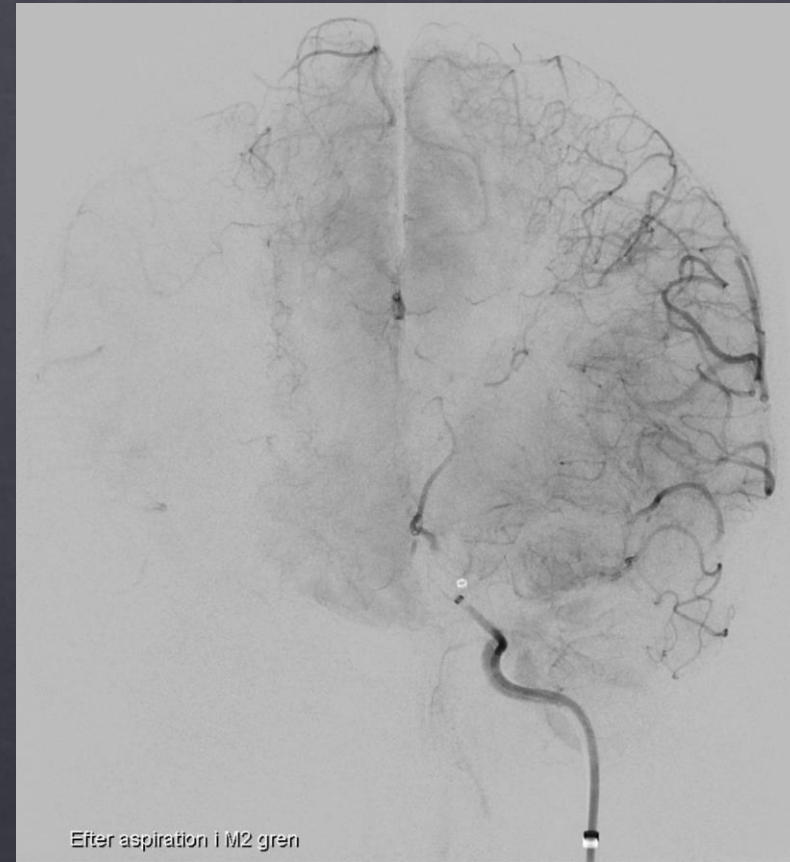
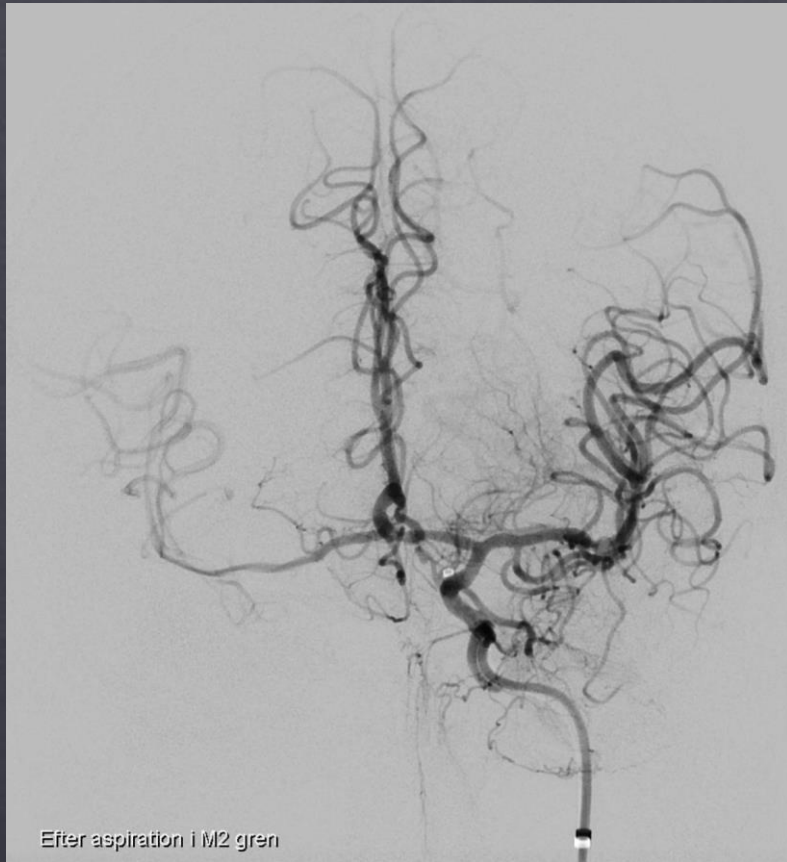


# After aspiration i ACI

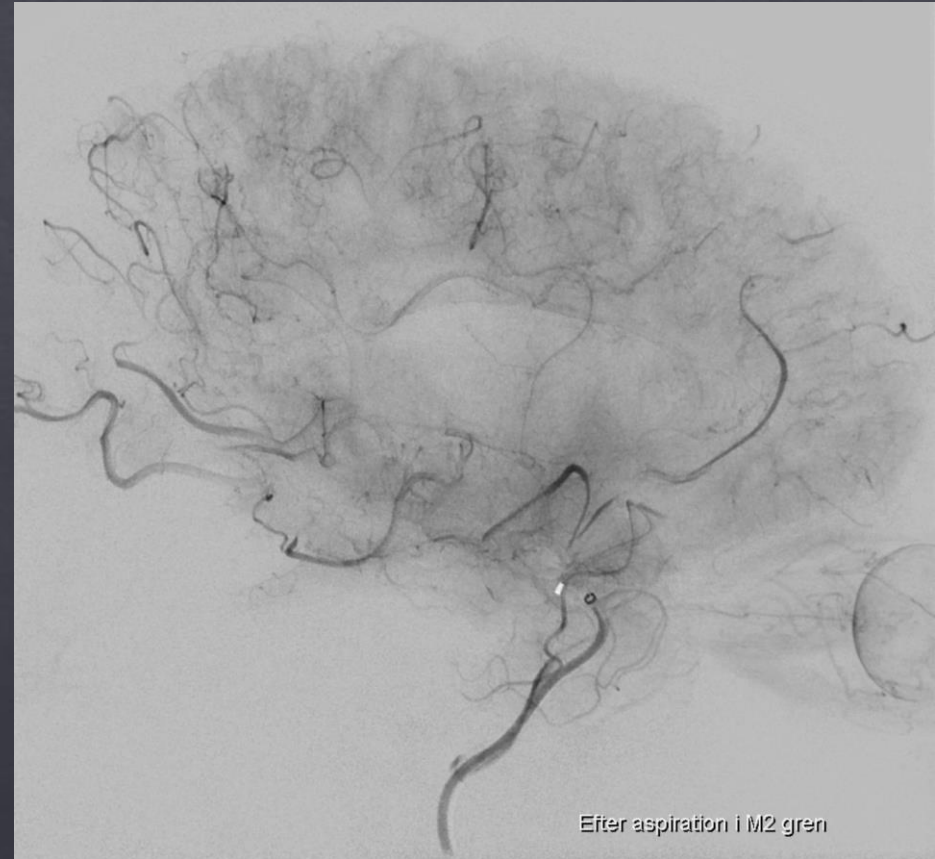
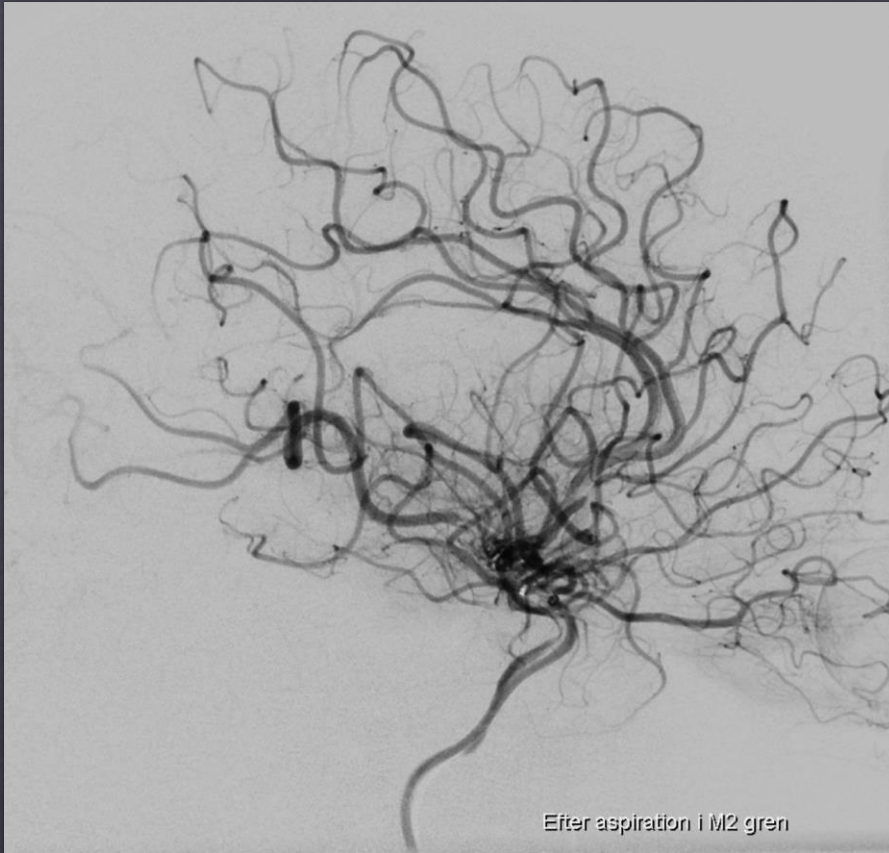




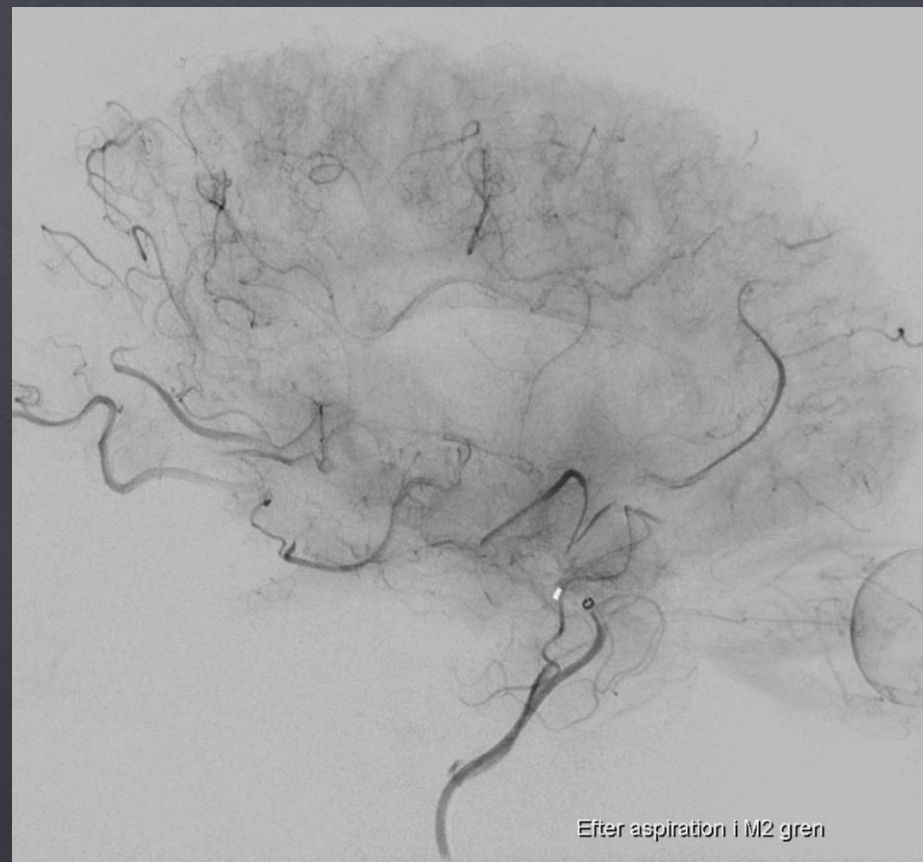
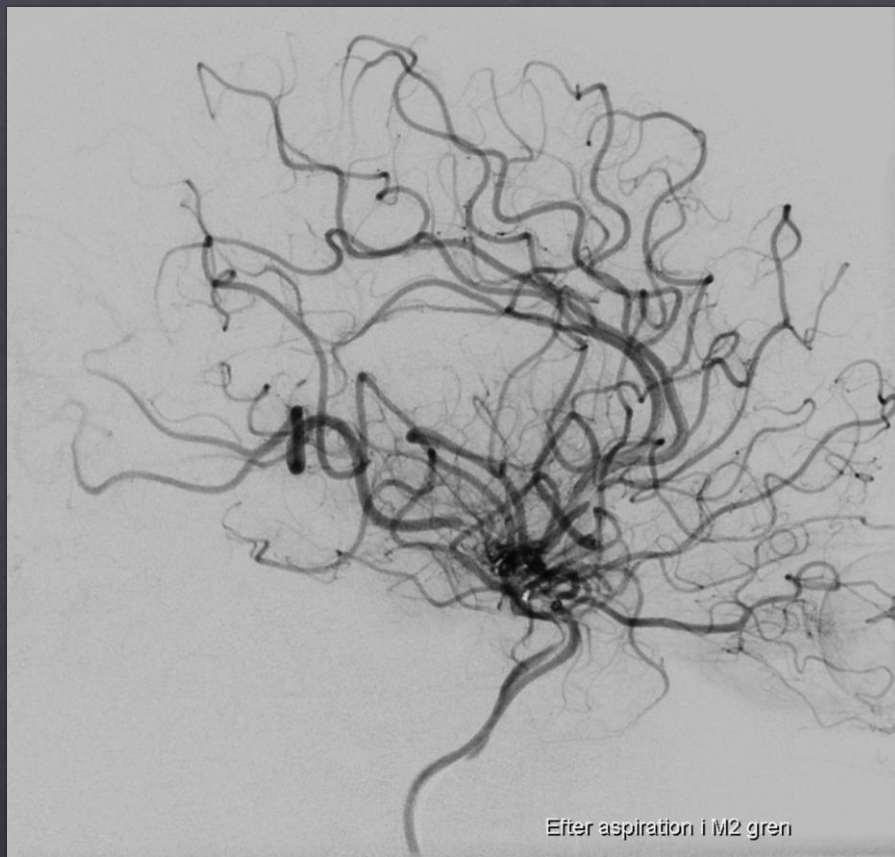
# Efter aspiration i M2 og stent retriever i A2



# Efter aspiration i M2 og stent retriever i A2

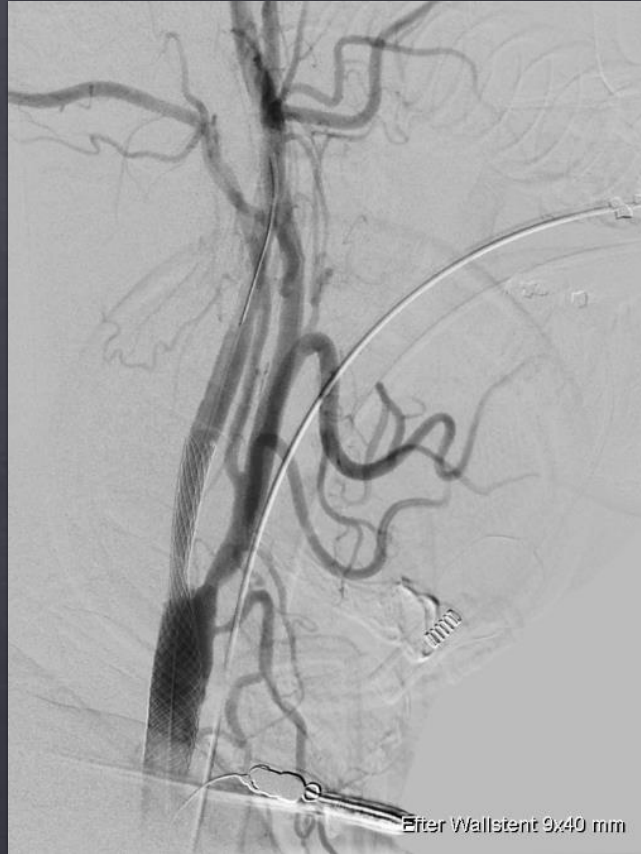

# TICI 2b

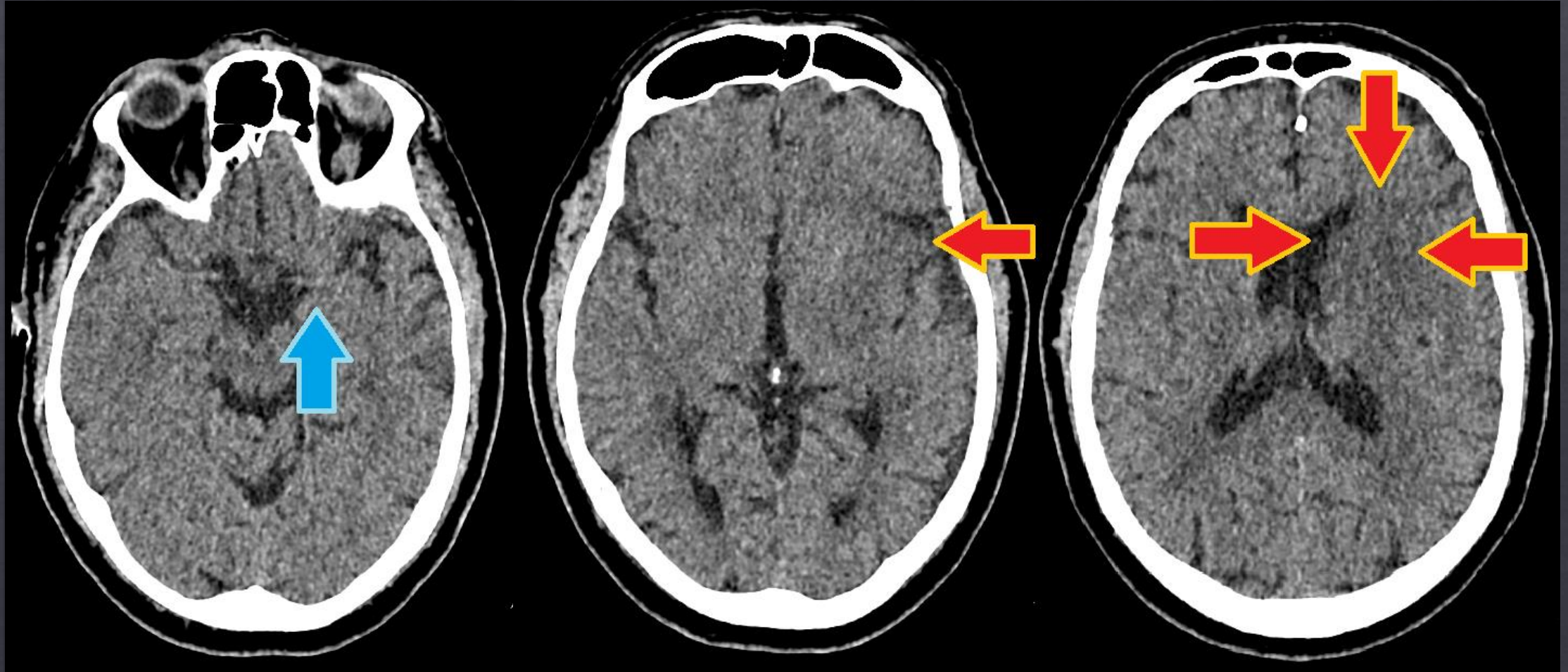




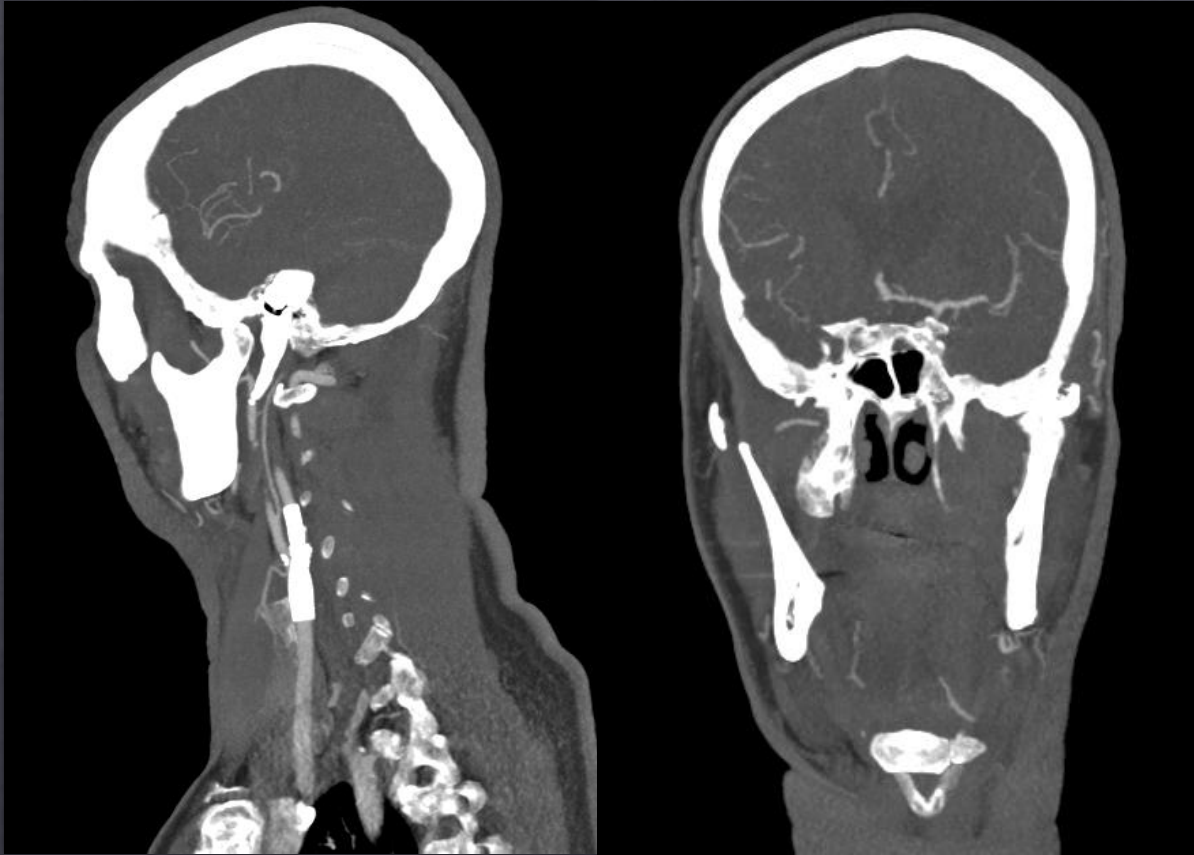
# I rolig fase



Kontrol 24 h



# 3mdr kontrol



- ◇ Let fin ataksi.
- ◇ Helt diskrete afatiske træk
- ◇ Går frit uden hjælpemidler.
  
- ◇ Stadig sygemeldt, men regner med at vende tilbage til arbejde.



# Når enden er god er alting godt.



- ◇ Kronisk stenose på ICA bilateralt.
- ◇ Været delvist forsynet via collateraler
- ◇ Pludselig aflukning af venstre ICA
  
- ◇ Vanskelig trombektomi sv.t. venstre ICA/M2/A2 samt Wallstentning af venstre ICA med PTA efter 3 aspirationer og 1 stentassisteret aspiration - TICI 2b
  
- ◇ NIHSS 25 → NIHSS 6 → NIHSS 2



# Cerebral angiografi

